TNM EN PATOLOGIA: PER QUÈ? COM?

CÀNCER DE MAMA

Dr. JMª Corominas. Patología
Hospital del Mar
Dr. I. Tusquets. Oncología Mèdica.
Hospital del Mar
Dr. A. Pedro. Radioteràpia.
Hospital Plató

Pierre Denoix
(1912-1990)



1ª Ed (1977)









4ª Ed (1992) **5ª Ed (1997)** **6ª Ed (2002)** **7ª Ed (2009)**

pT (UICC - 2009)



TAMANY (Mida) TUMORAL

cT

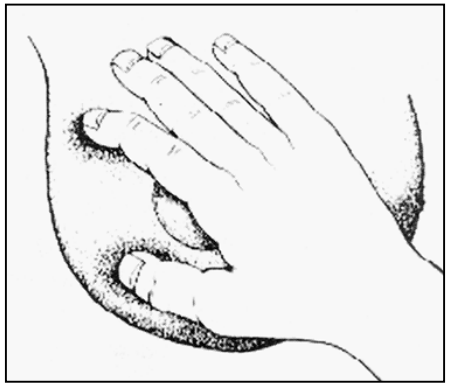

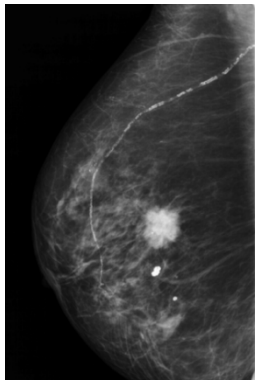

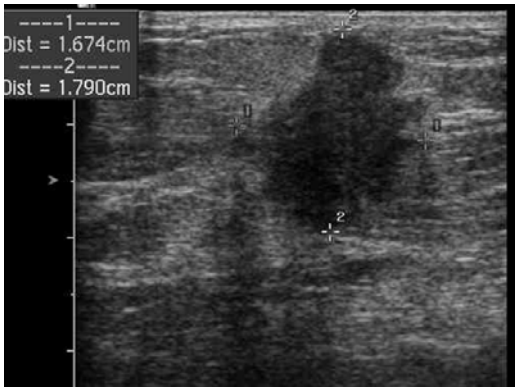

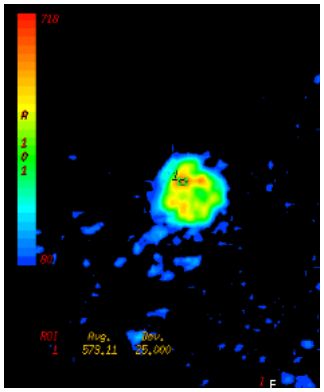

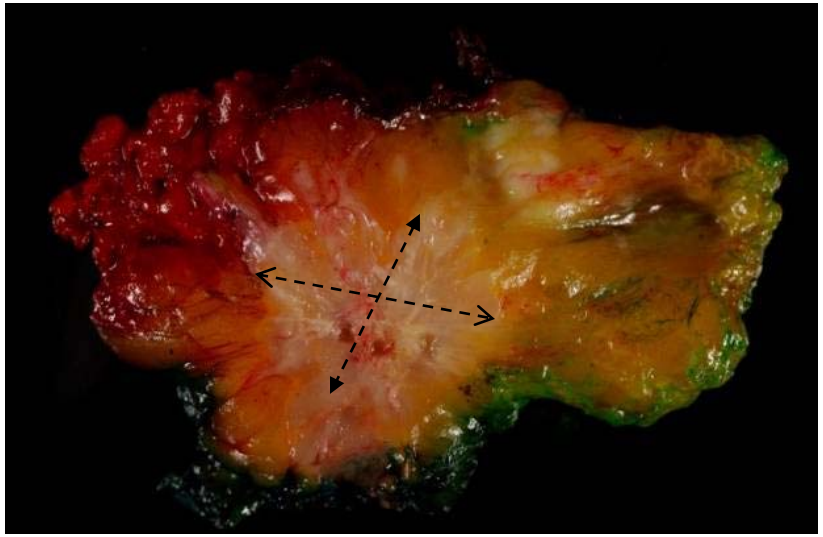

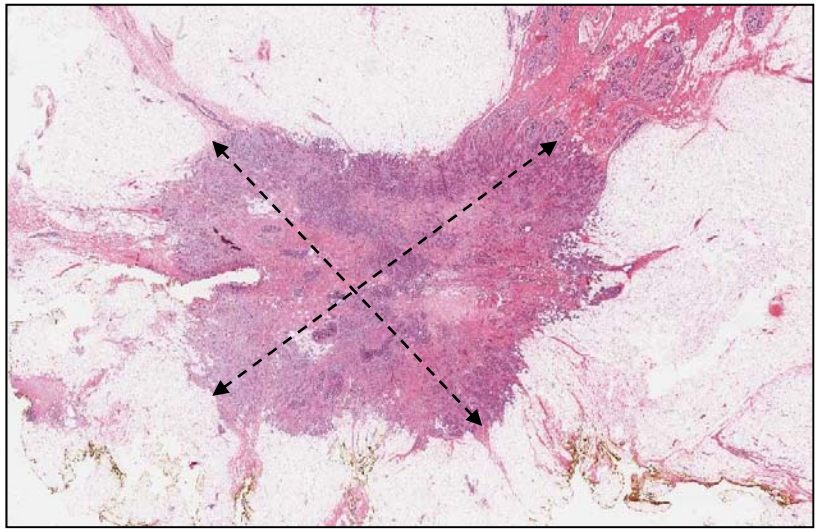

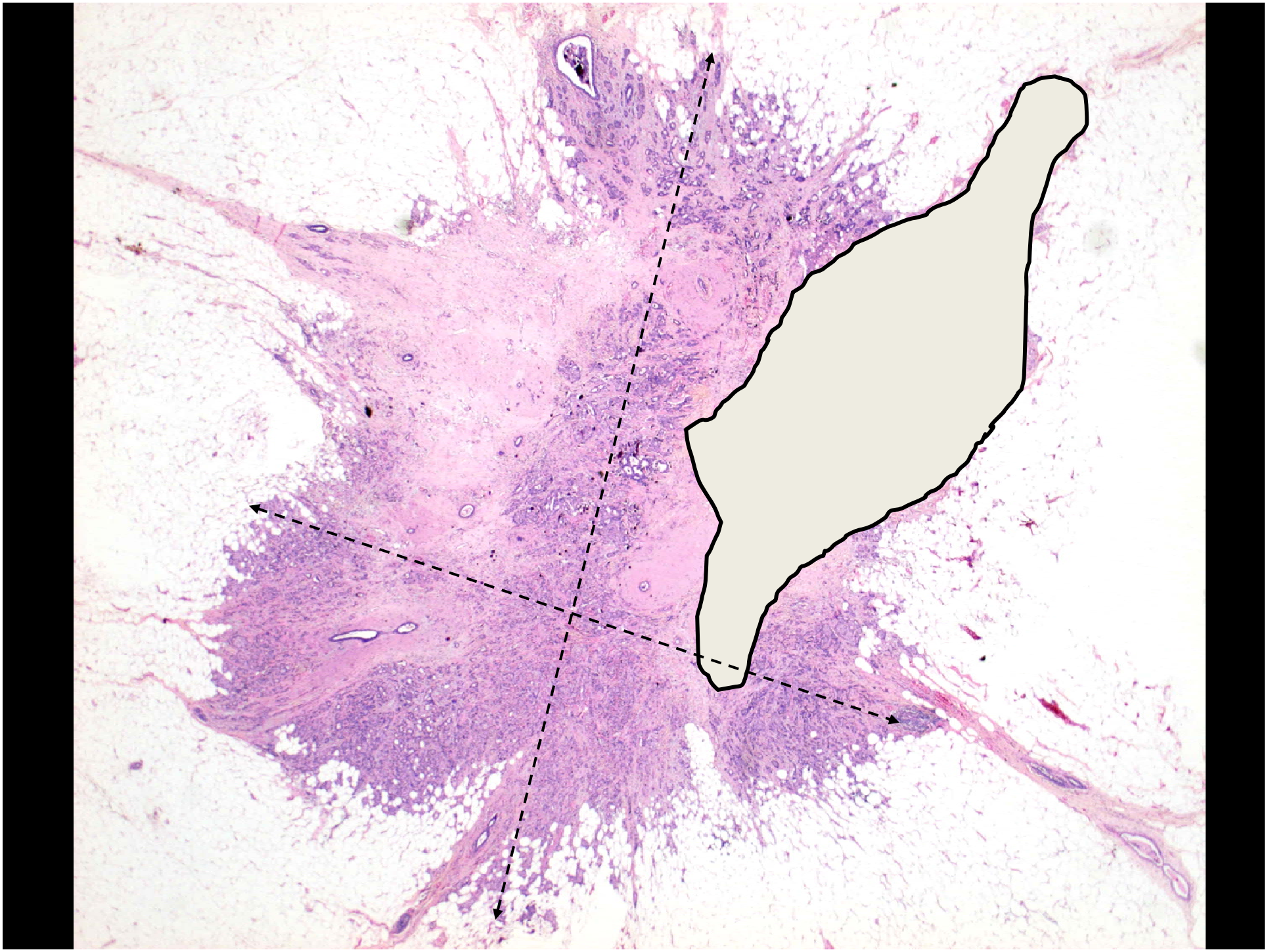

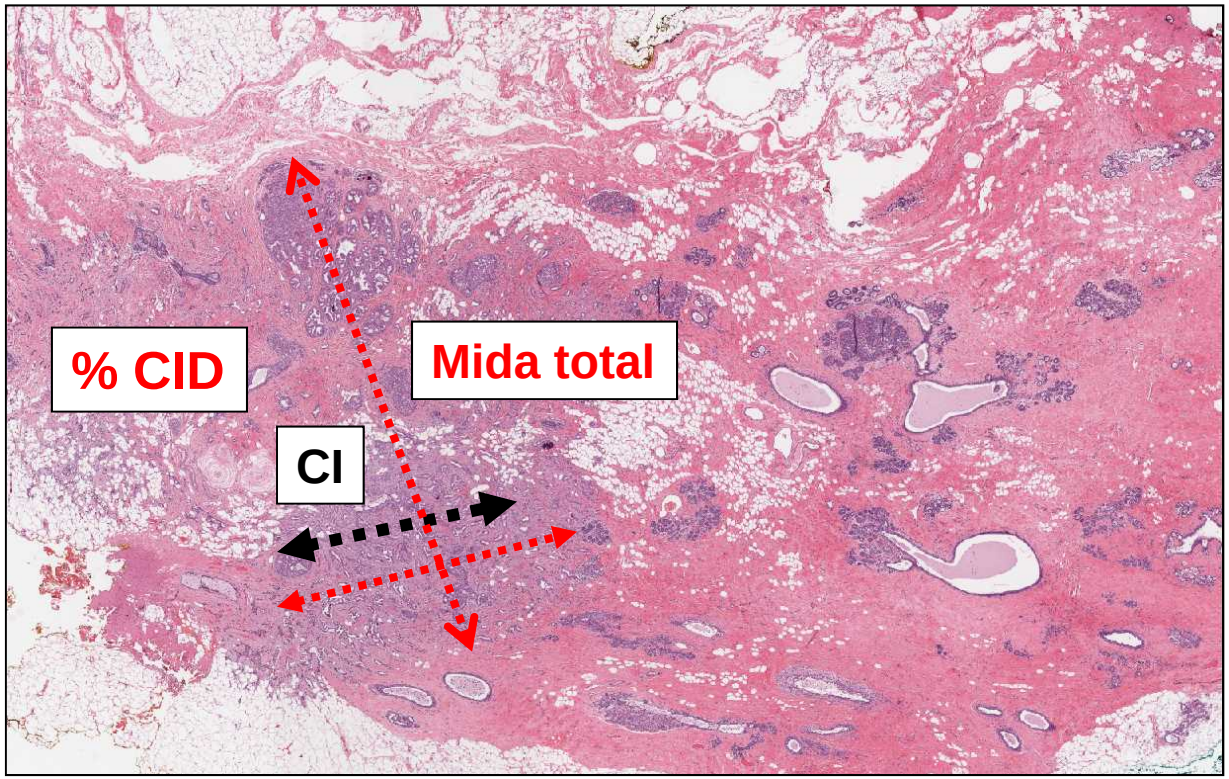
% CID
Mida total
CI

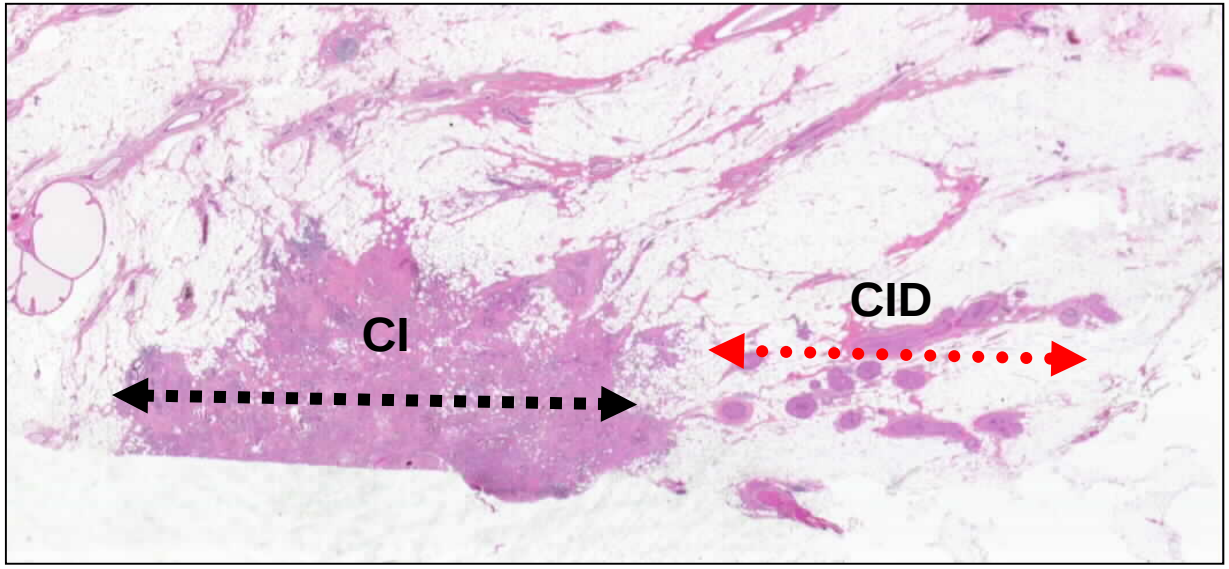
CI
CID

pT (UICC - 2009)



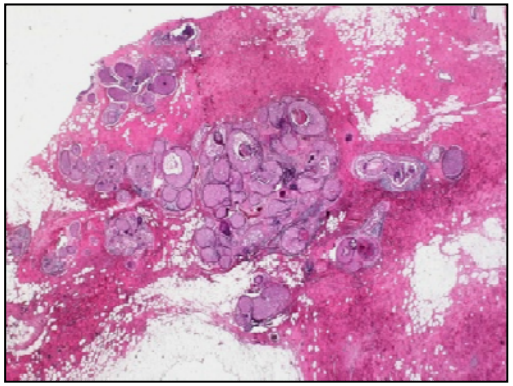

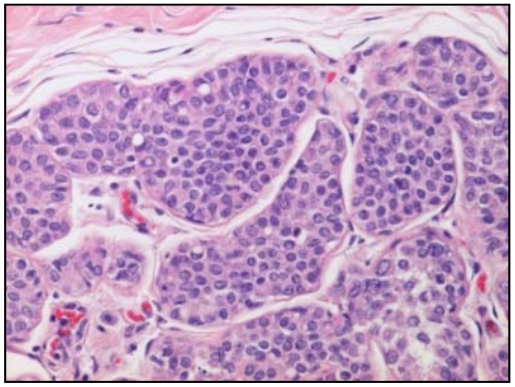

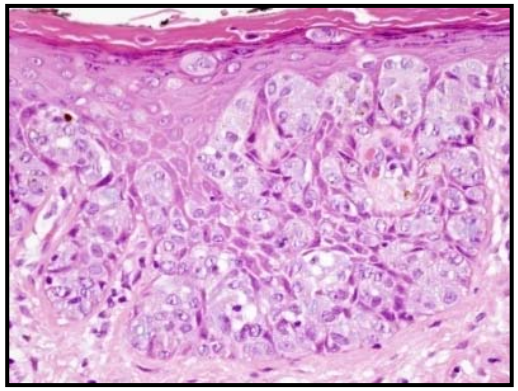

pTx (no avaluable)

pTis (carcinoma in situ)

- **Tis (DCIS) (carcinoma ductal in situ)**
- **Tis (LCS) (carcinoma lobel·lar in situ)**
- **Tis (Paget) (malaltia de Paget sense carcinoma in situ ni infiltrant)**

MALALTIA DE PAGET

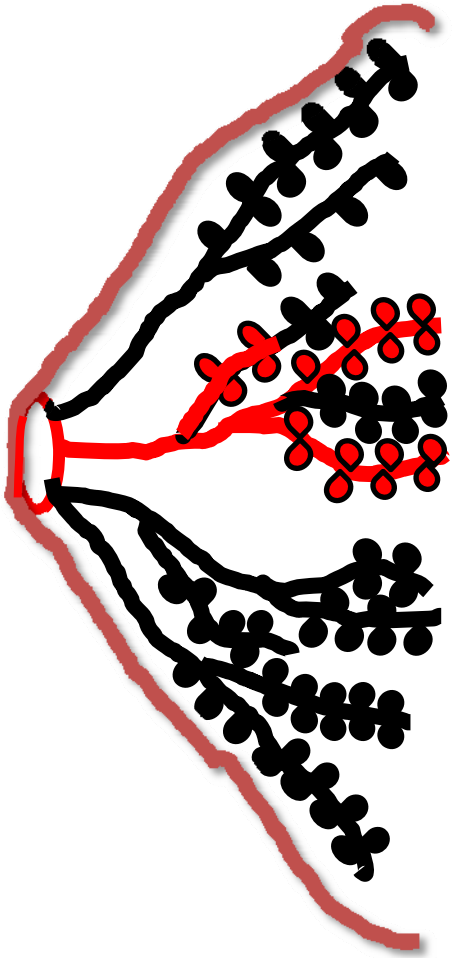

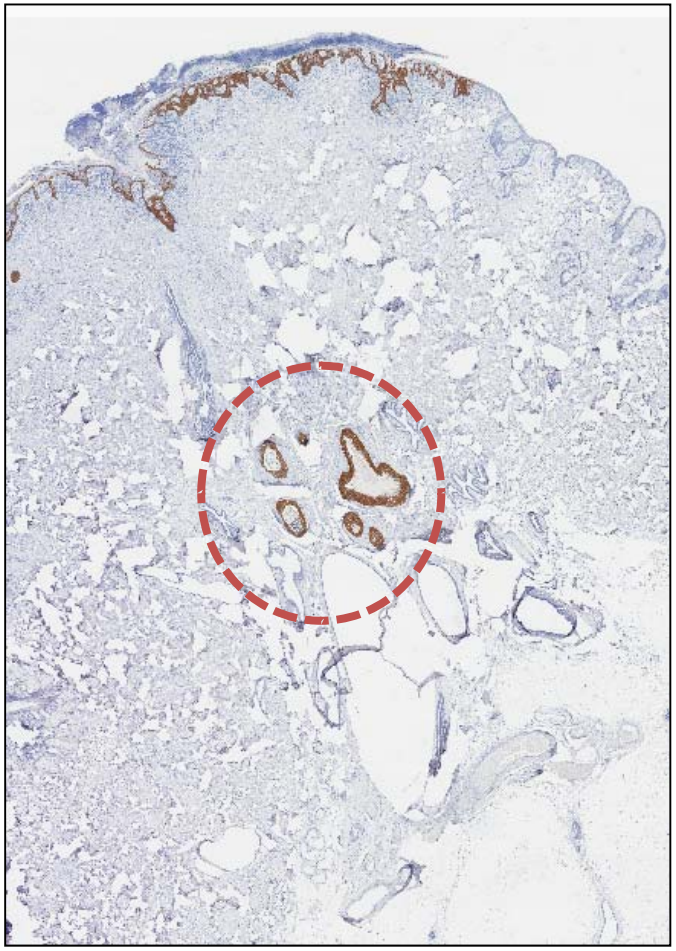

pTis (DCIS) amb malaltia de Paget

MALALTIA DE PAGET

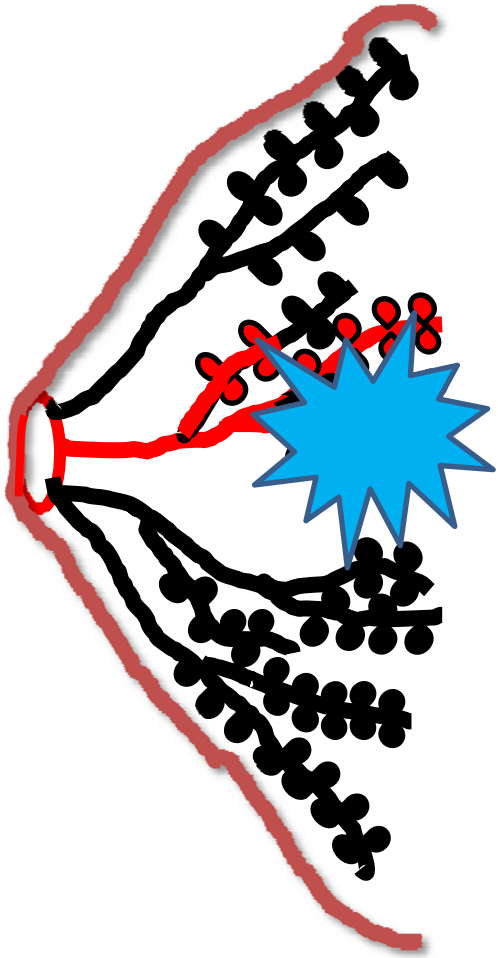

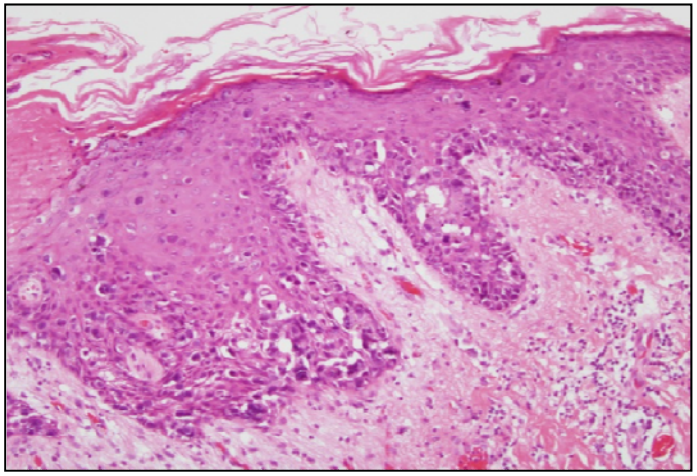

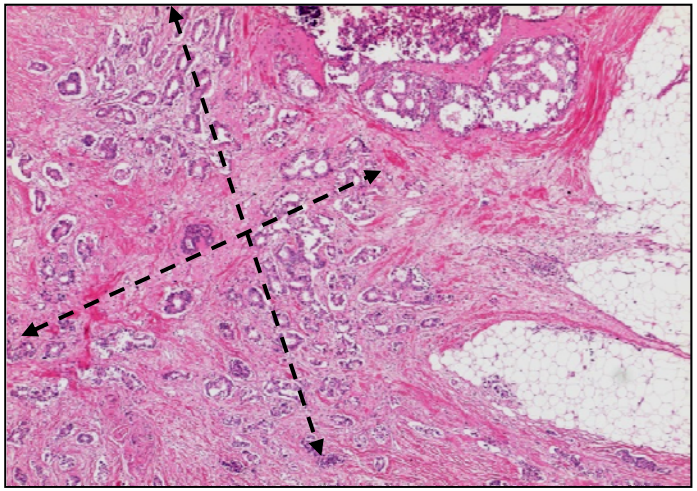

pT..... amb malaltia de Paget

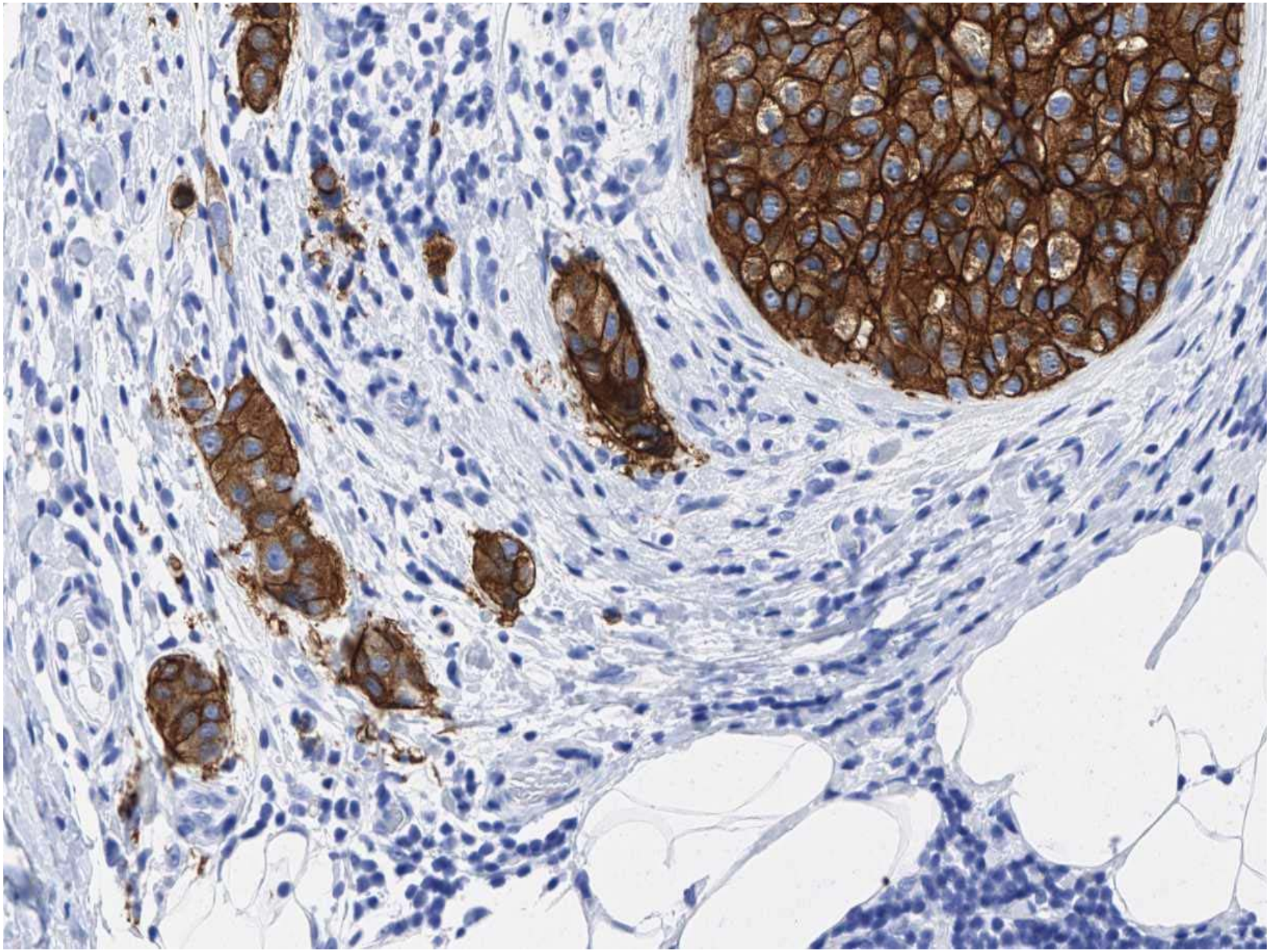

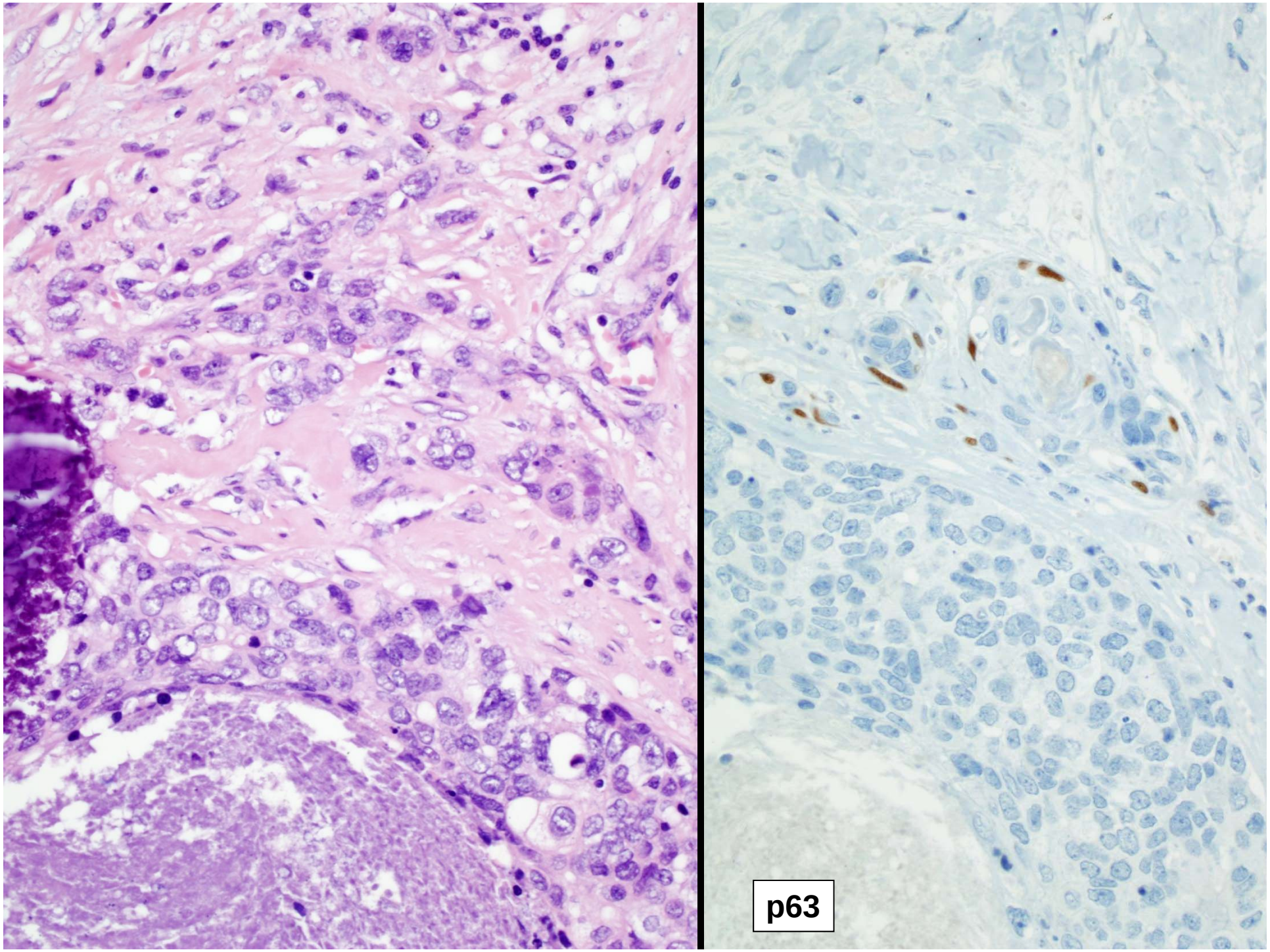
p63

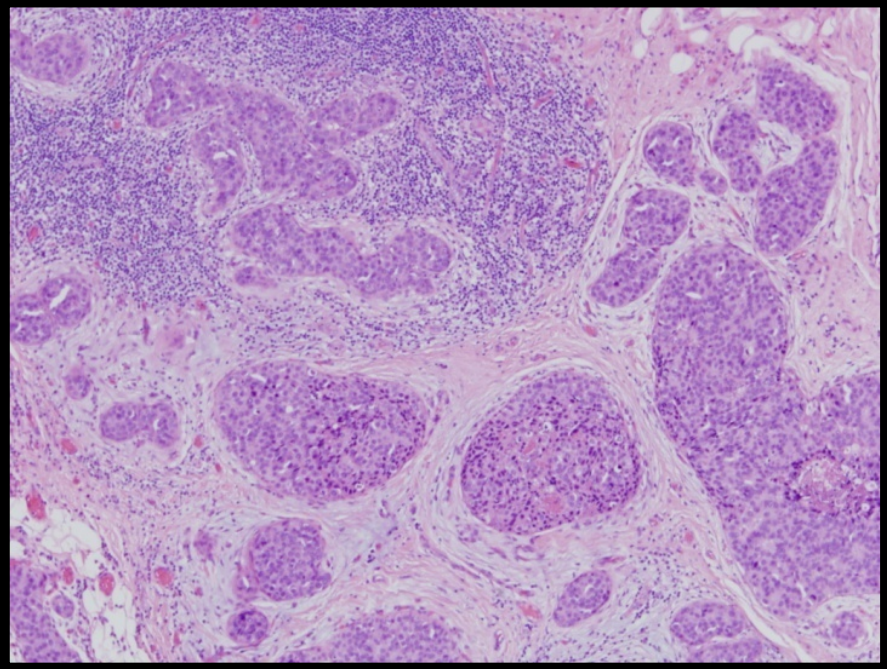

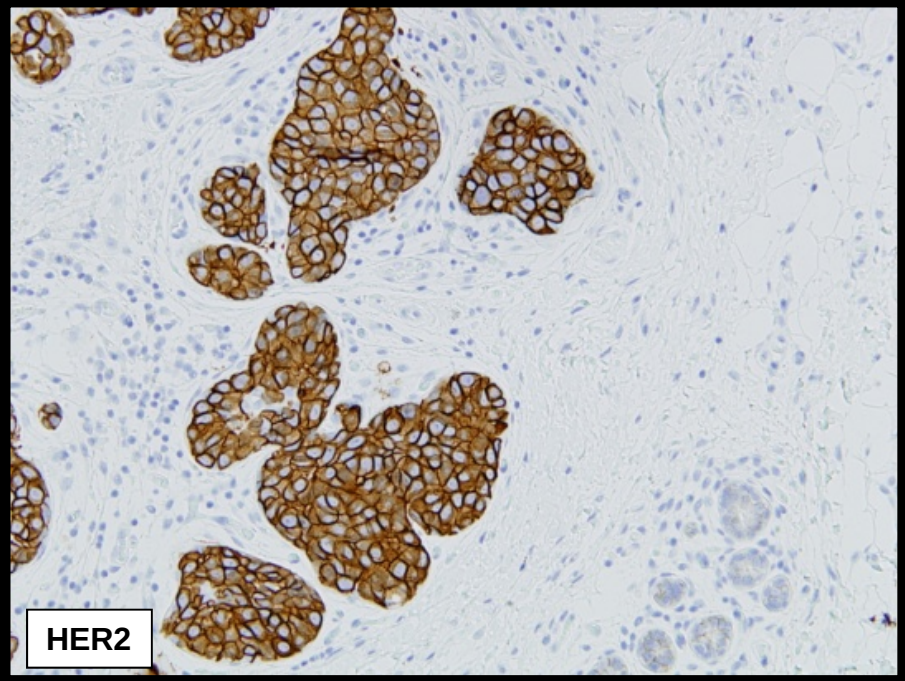
HER2

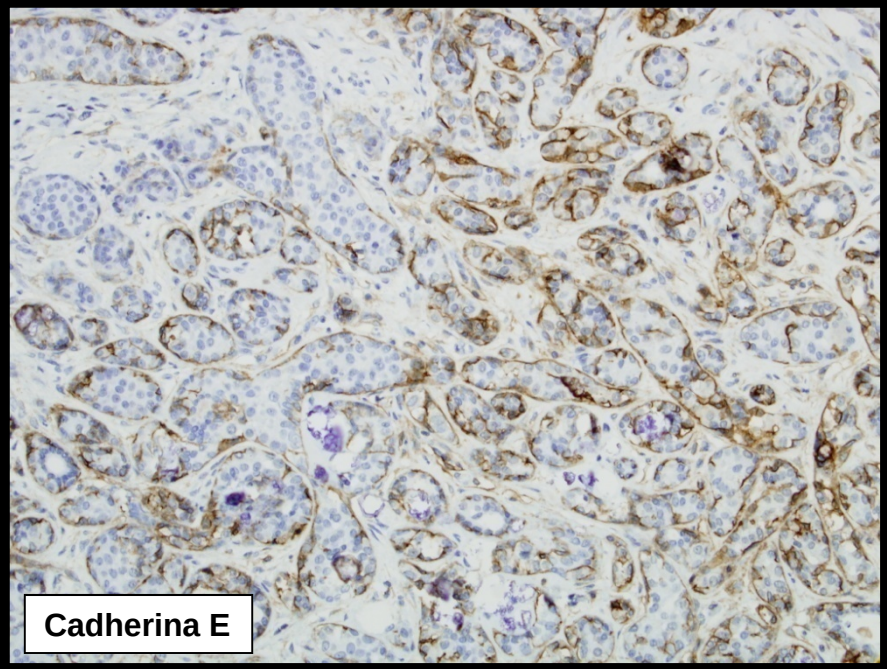
Cadherina E

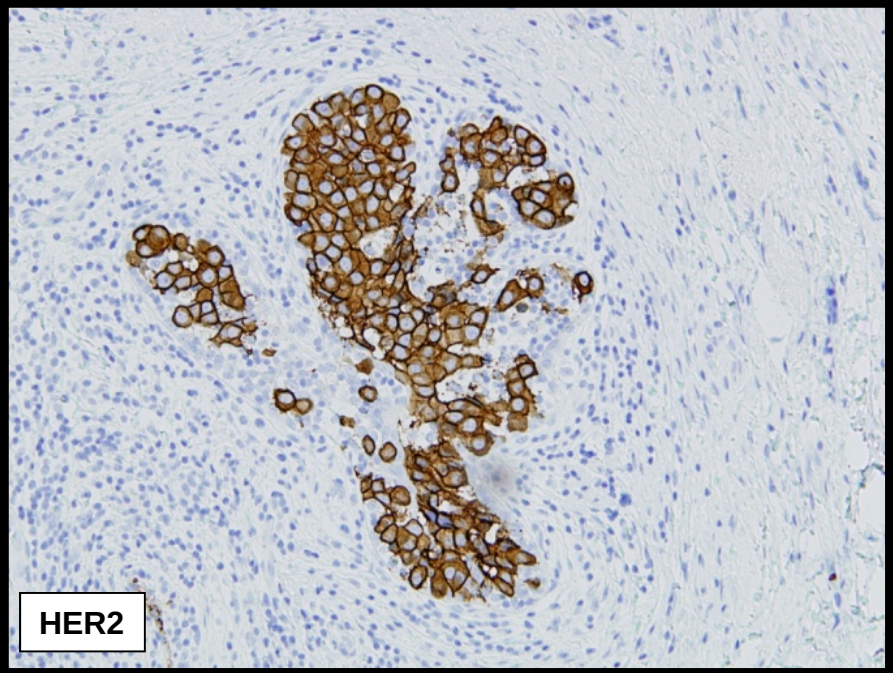
HER2

pT (UICC - 2009)



pT1 mic (Carcinoma microinvasiu <= 1 mm)

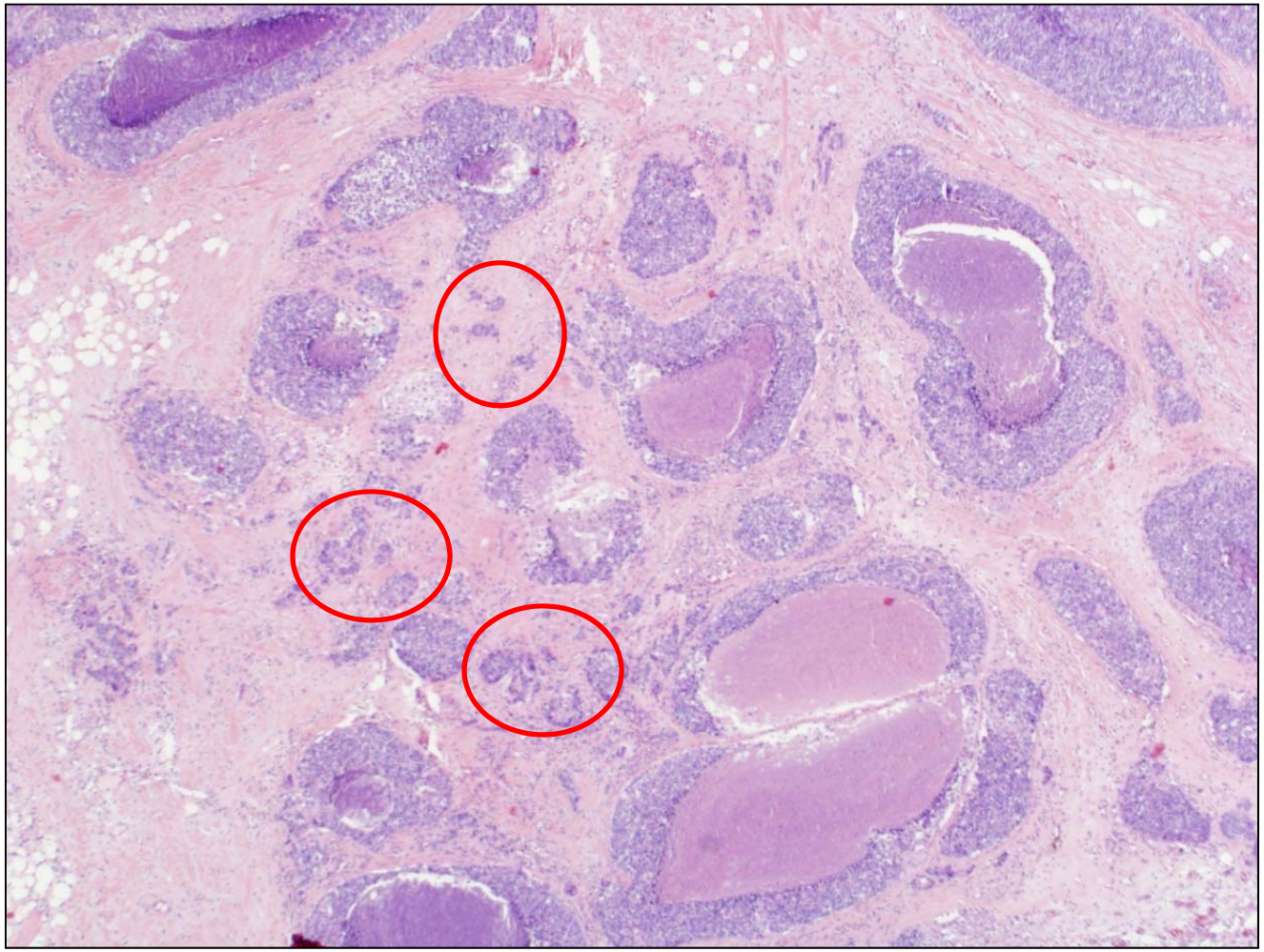

pT (UICC - 2009)



pT1 mic (Carcinoma microinvasiu <= 1 mm)



OMS 2003



Microinfiltració: Un focus de fins 2 mm, o bé fins 3 focus de < 1 mm

Els casos de > 3 focus amb > 90% de DCIS els cataloguem pel T del component infiltrant per exemple pT1a (multi), especificant CARCINOMA INFILTRANT AMB EXTENS COMPONENT INTRADUCTAL (indicant >90%)

pT (UICC - 2009)



pT1 (< 2 cm)

- pT1a (> 1- 5 mm)
- pT1b (> 5-10 mm)
- pT1c (> 10-20 mm)

pT2 (> 20-50 mm)

pT3 (> 50 mm)

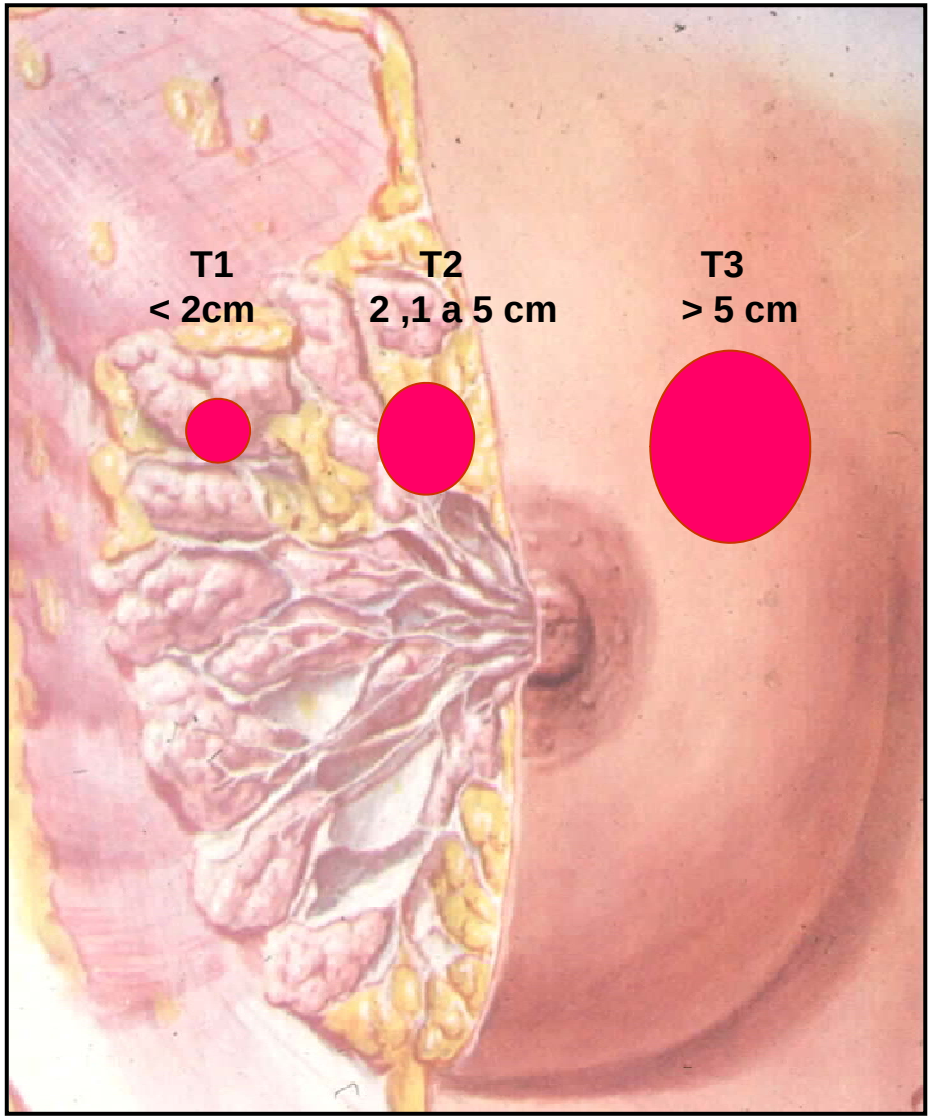

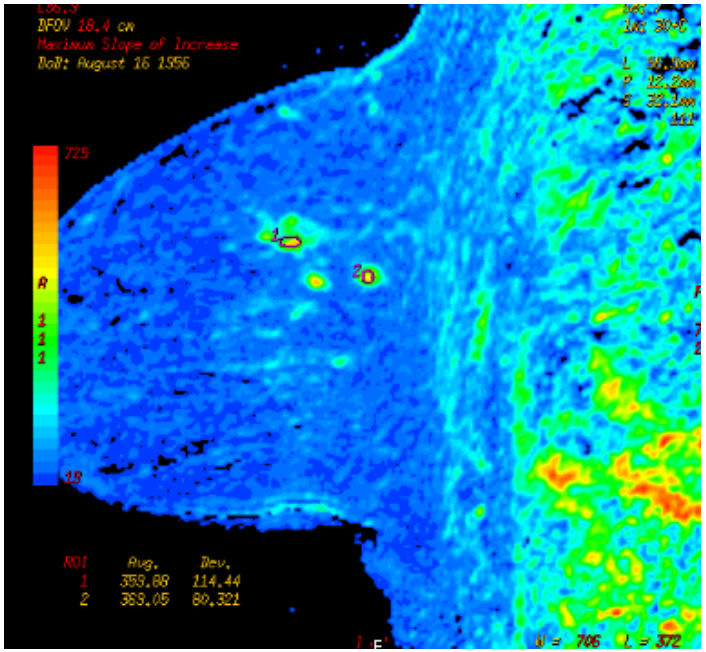
DFOV 18.4 cm
Maximum Slope of Increase
Date: August 16 1556
725
A
1
1
1
48
ROI Avg. Dev.
1 353.88 114.44
2 383.05 80.321

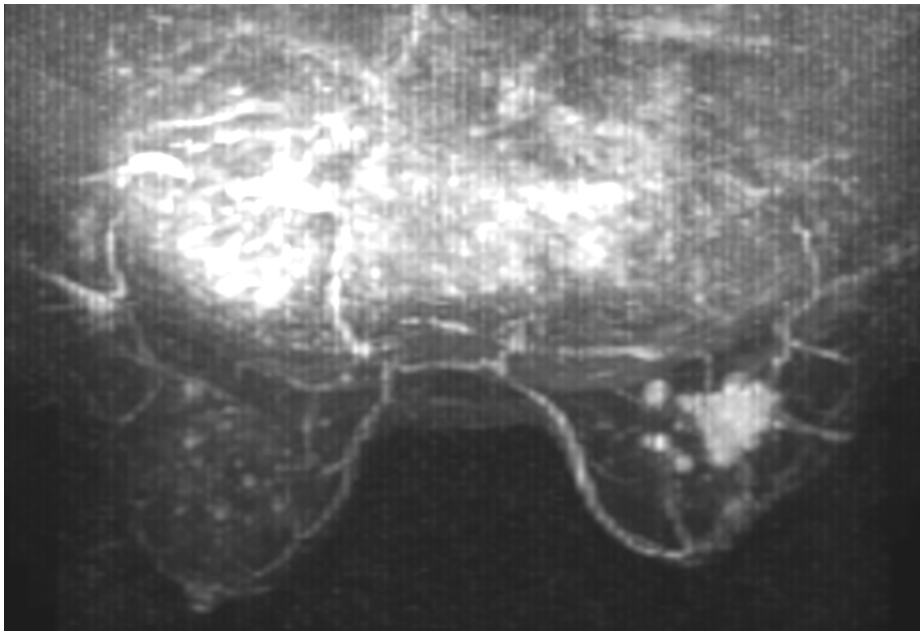

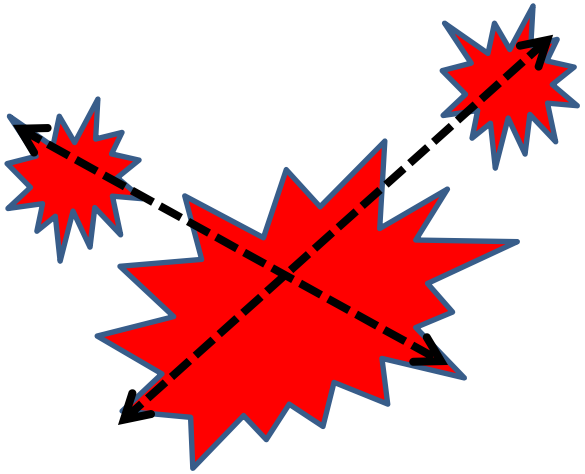

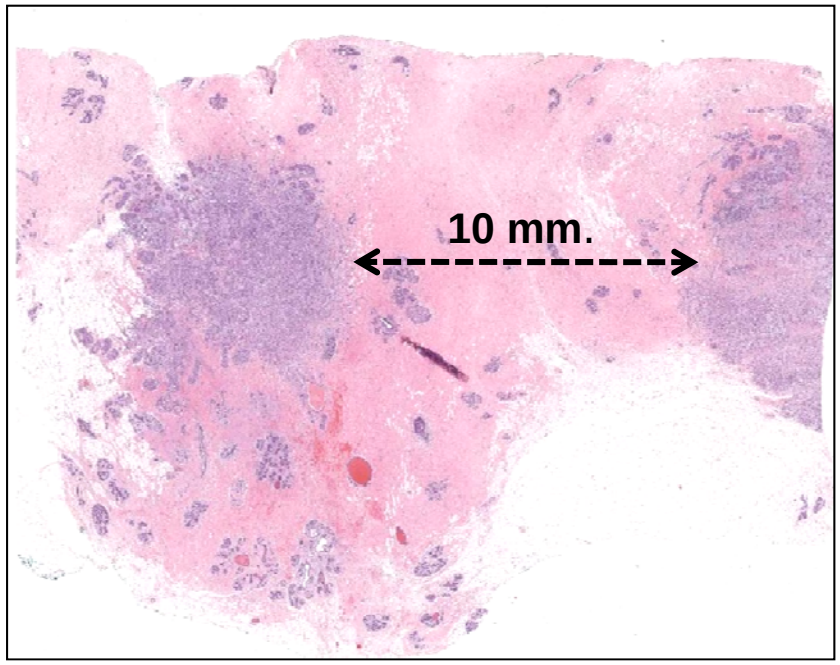
10 mm.



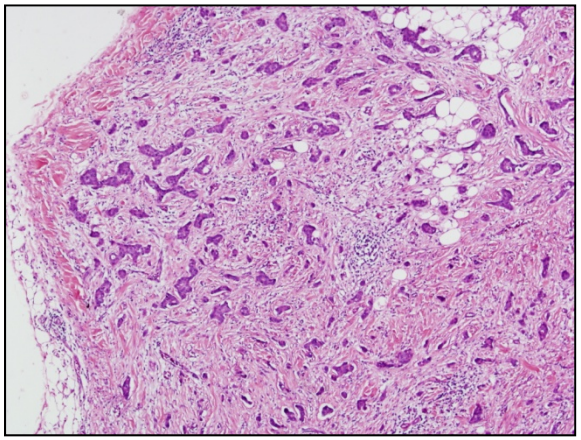

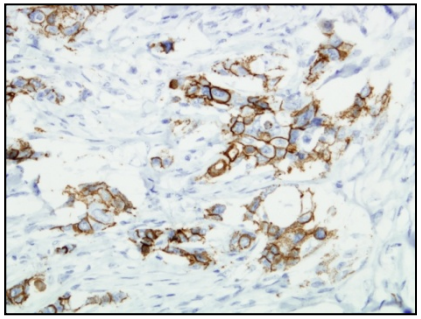

Tumor A: CDI

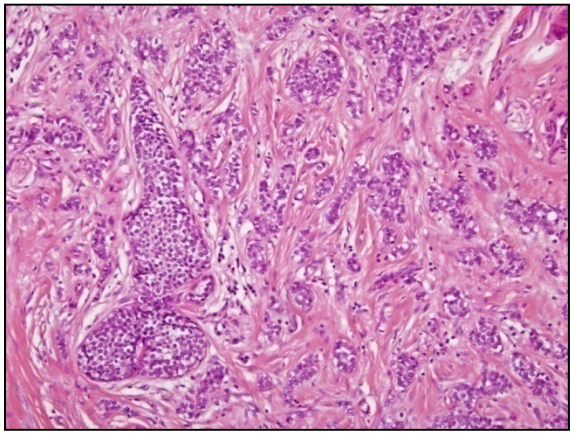

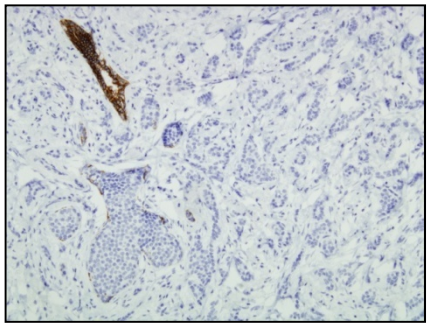

Tumor B: CLI

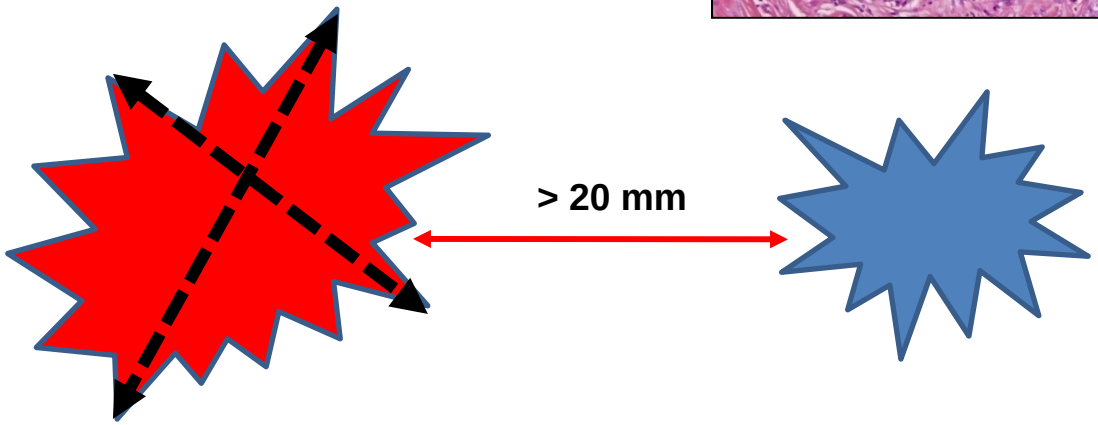

pT (UICC - 2009)



pT4 (qualsevol T amb invasió a pell o paret toràcica)

pT4a (invasió paret toràcica, no invasió múscul pectoral)

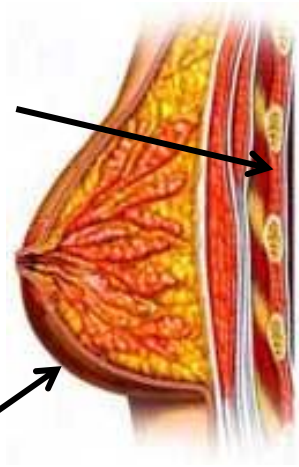

pT4b (edema, incloent pell taronja, ulceració de la pell o nòduls satèl·lits a la pell de la mateixa mama)

pT4c (inclou el pT4a i pT4b)

pT4d (carcinoma inflamatori)

pT4a (UICC - 2009)



- **Qualsevol T amb invasió paret toràcica, no invasió múscul pectoral**

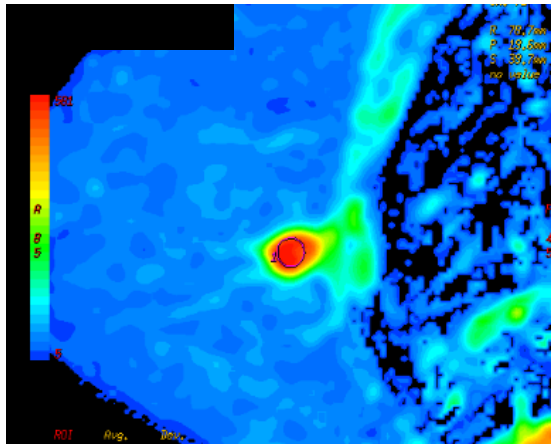

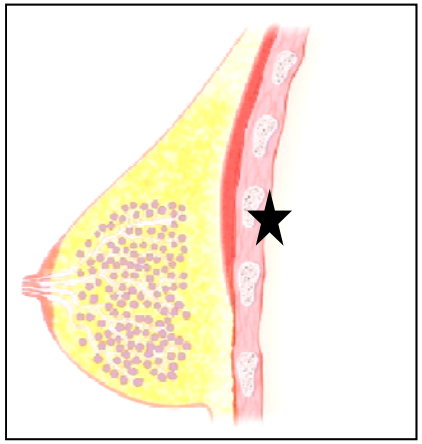

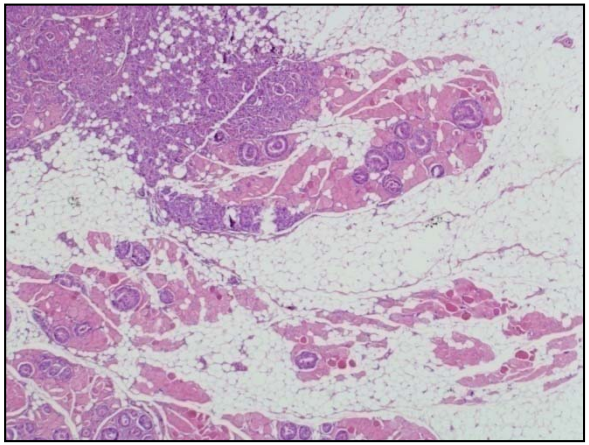

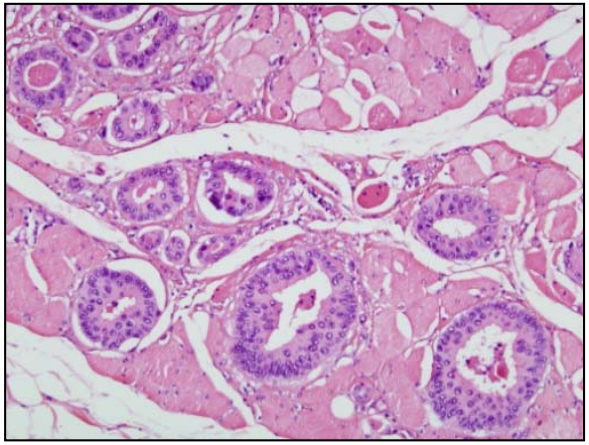

NO pT4a

pT..... Amb infiltració de mùscul pectoral

FÀSCIA DEL PECTORAL

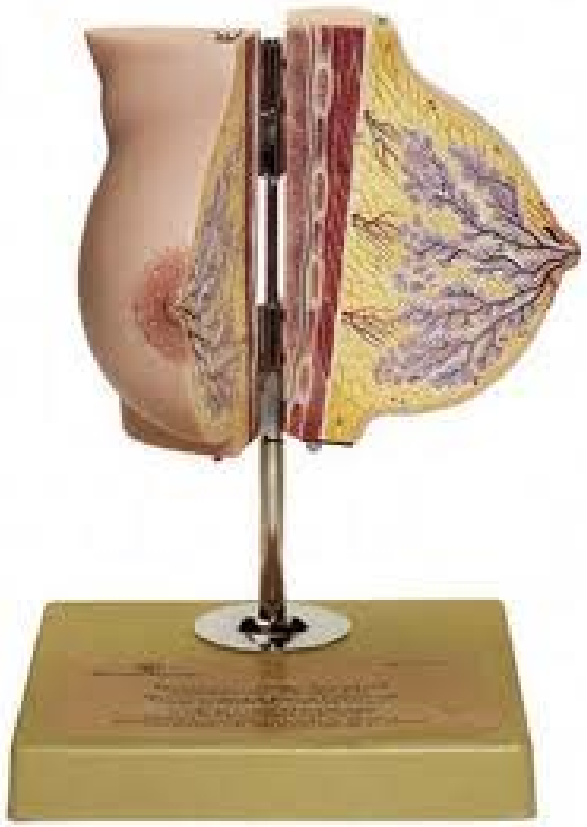

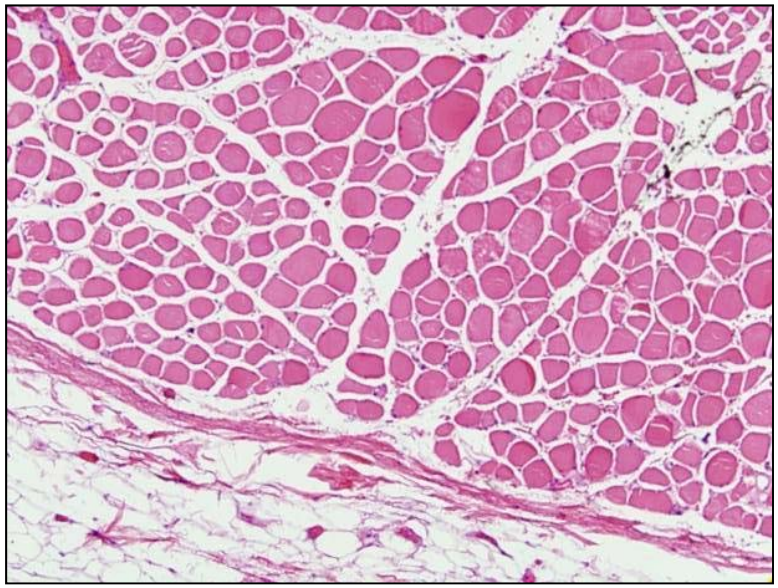

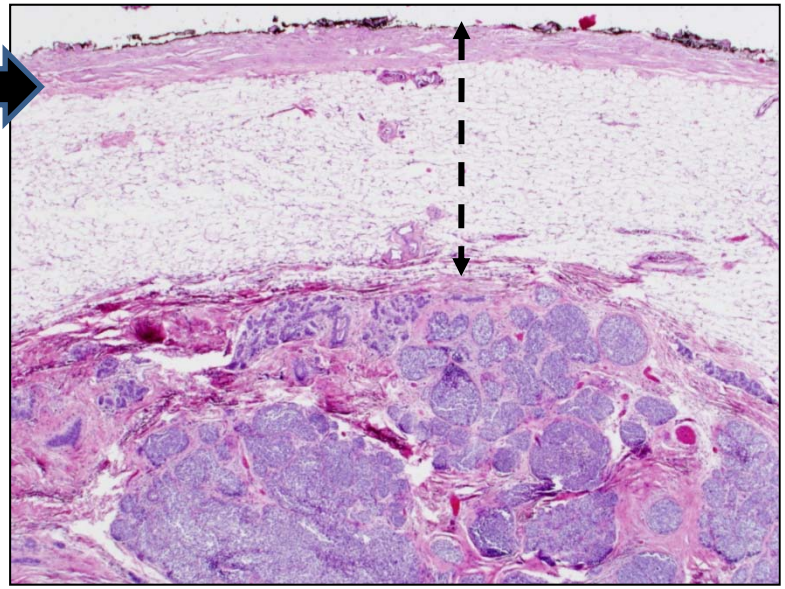

pT4b (UICC - 2009)



- **Qualsevol T amb edema, incloent pell taronja, ulceració de la pell o nòduls satèl·lits a la pell de la mateixa mama**

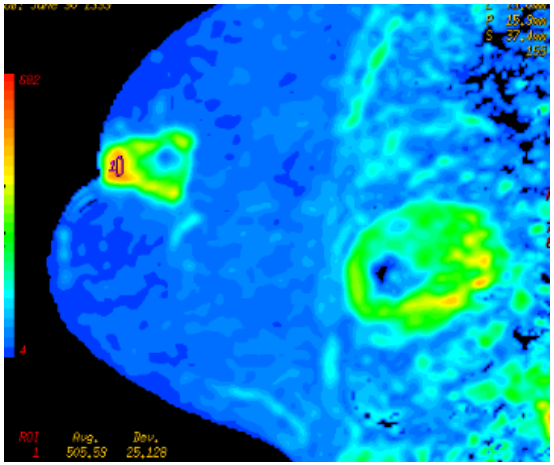

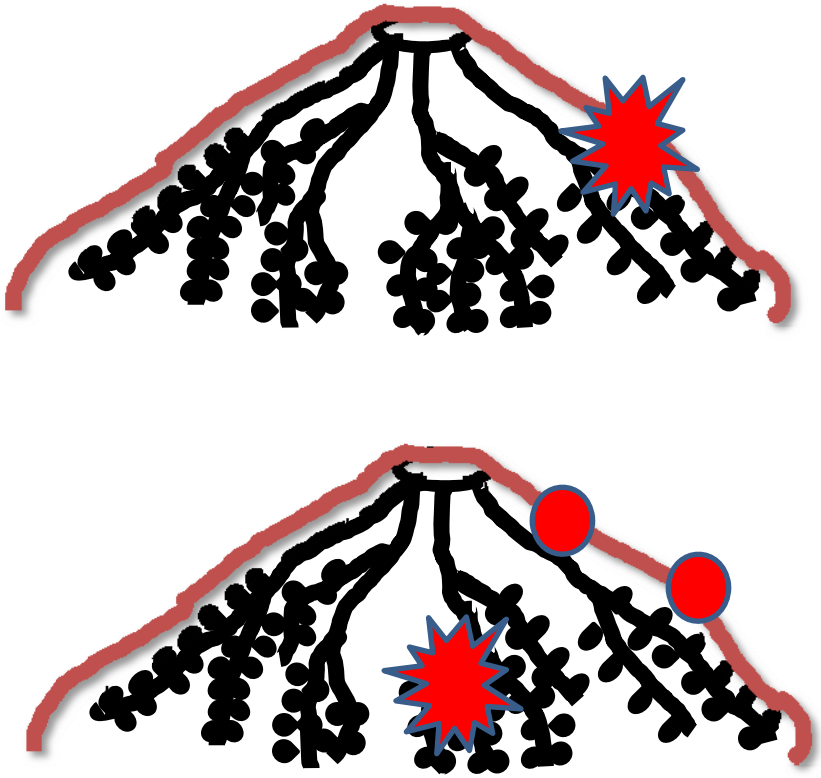

pT4b (UICC - 2009)



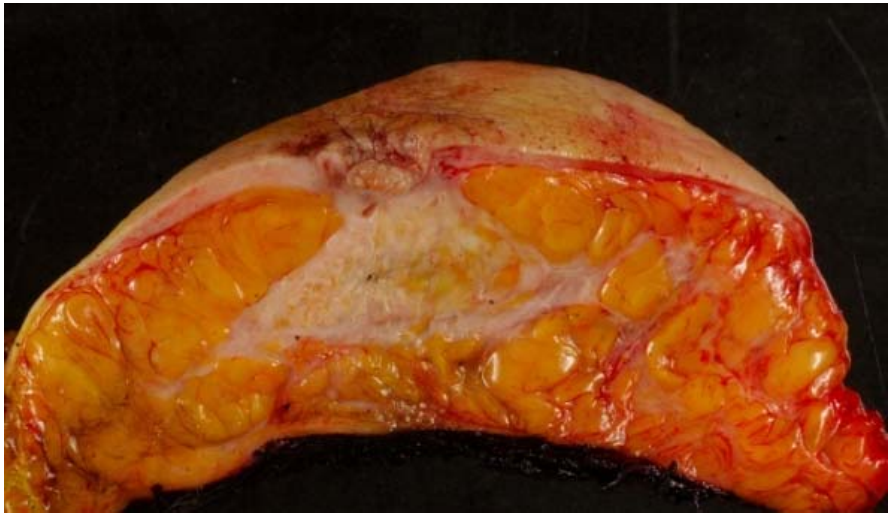

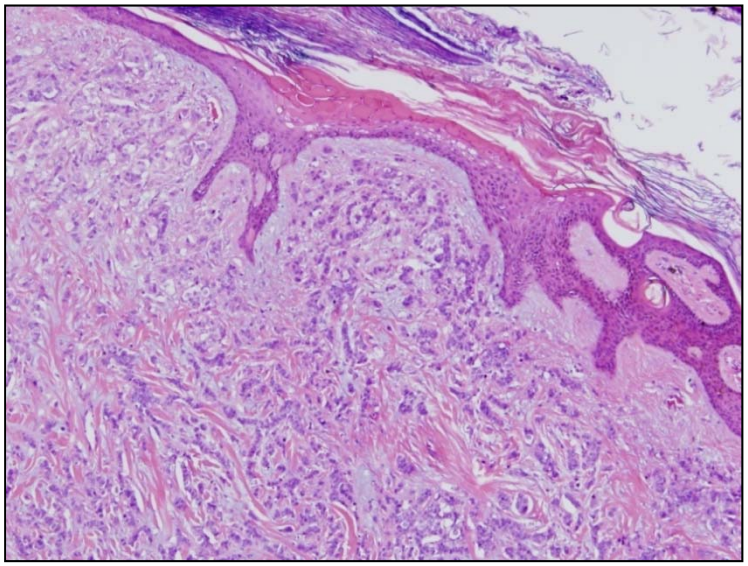

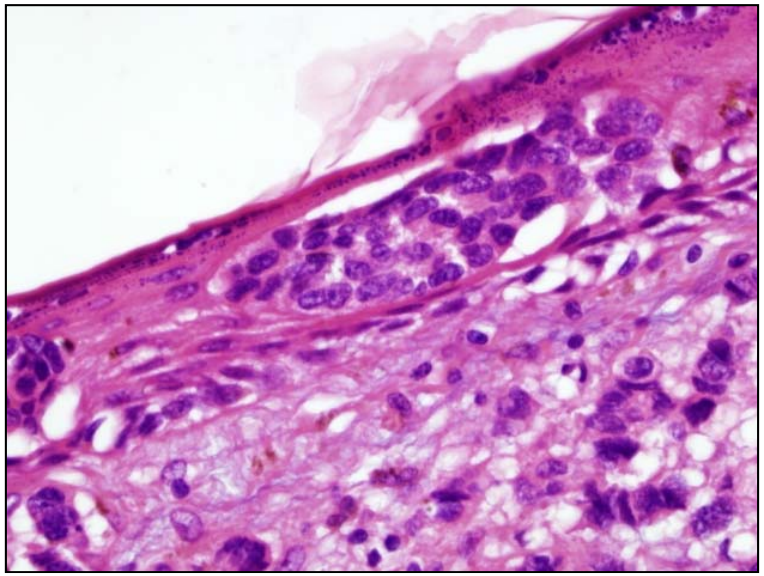

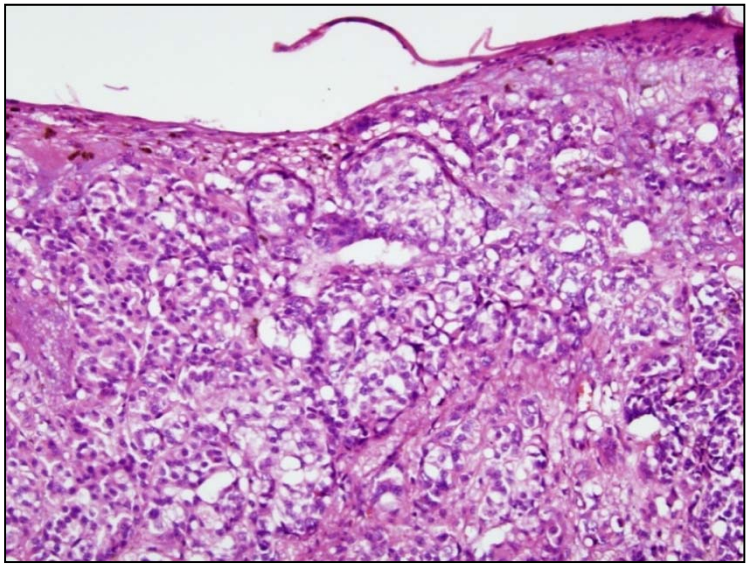

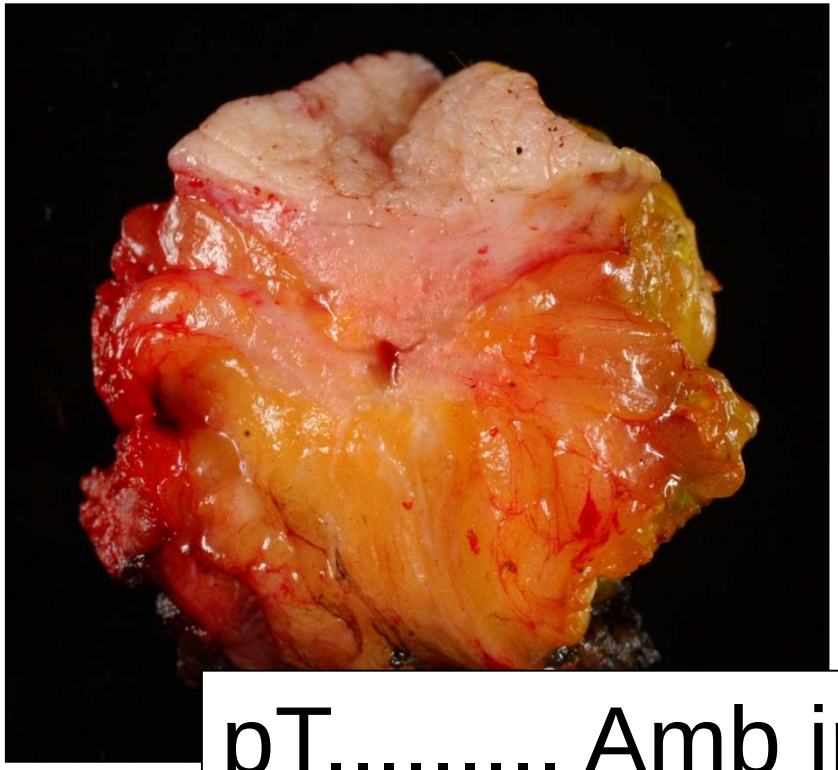

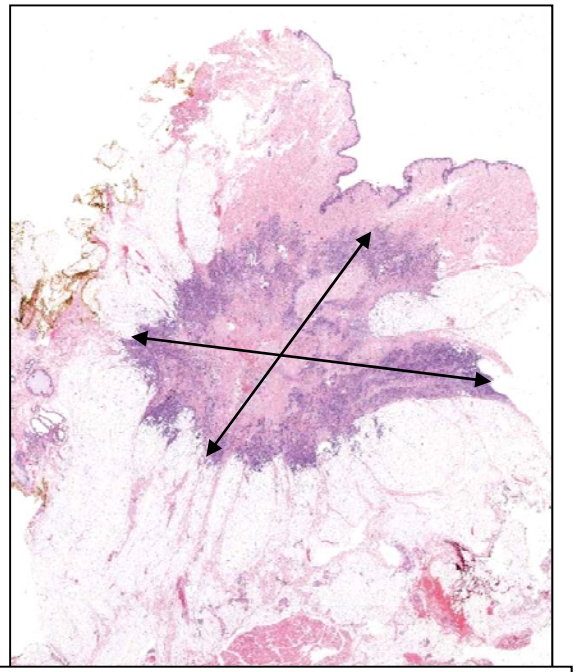

pT..... Amb infiltració dèrmica

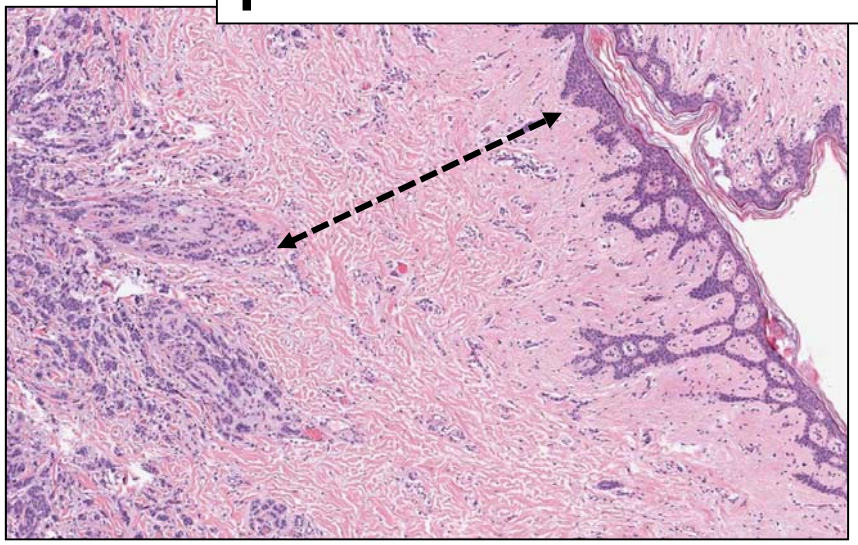

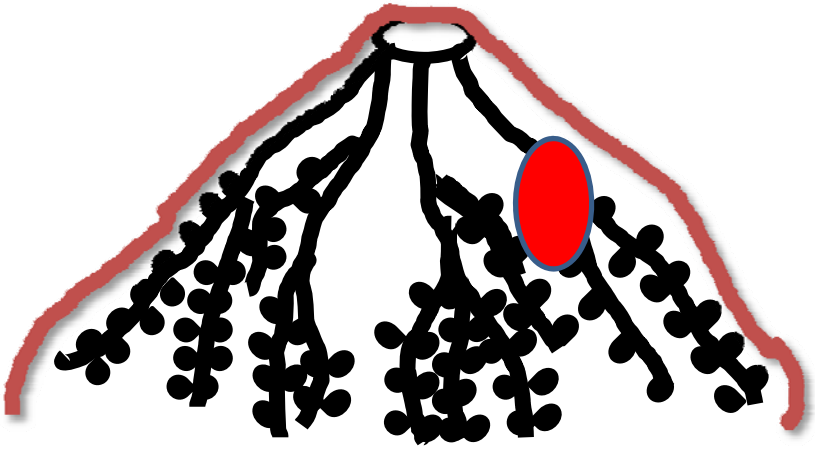

pT4c (UICC - 2009)



- **Inclou el pT4a i pT4b**

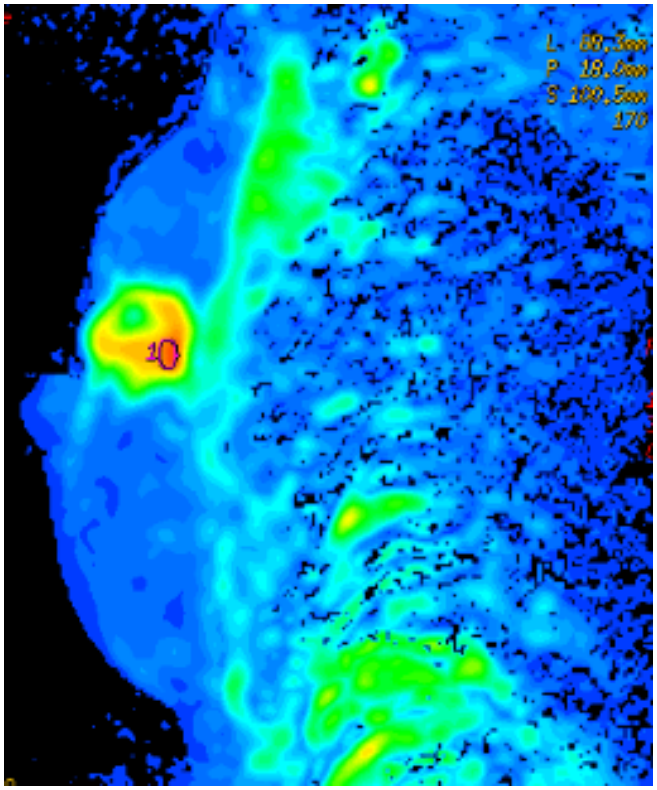

pT4d (UICC - 2009)



- **Carcinoma inflamatori**

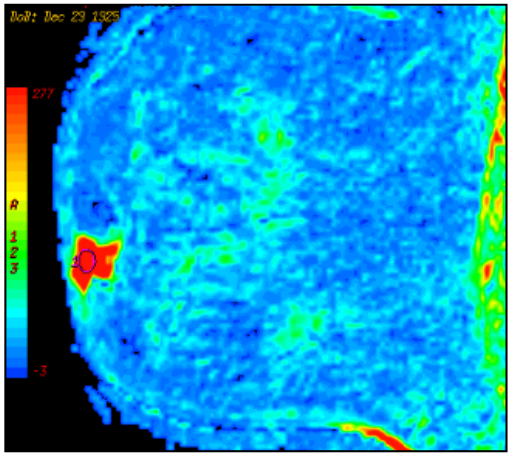

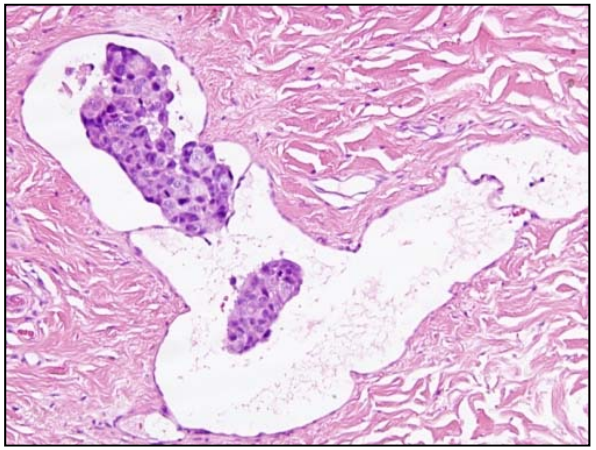

MARGES QUIRÙRGICS

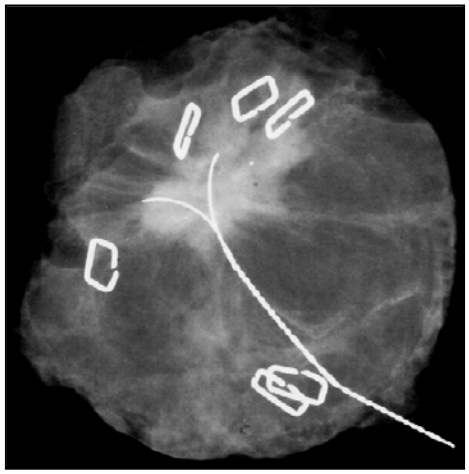

- ANTERIOR
- POSTERIOR
- SUPERIOR
- INFERIOR
- MEDIAL
- EXTERN

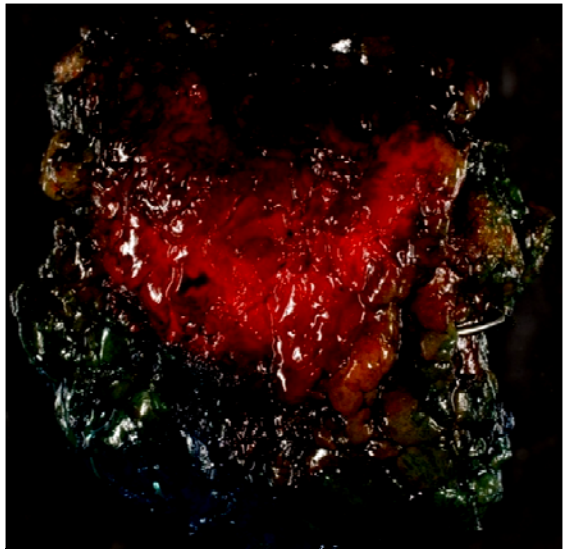

MARGES QUIRÙRGICS

(CAP – ONCOGUIA)

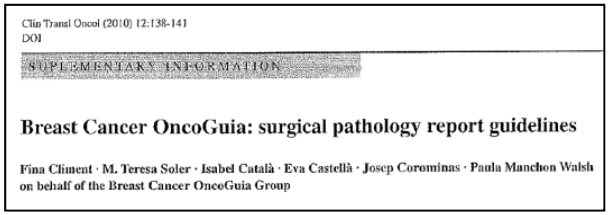
Clin Transl Oncol (2010) 12:138-141
DOI

SUPLEMENTARY INFORMATION

Breast Cancer OncoGuia: surgical pathology report guidelines

Fina Climent · M. Teresa Soler · Isabel Català · Eva Castellà · Josep Corominas · Paula Manchon Walsh on behalf of the Breast Cancer OncoGuia Group

LLIURES

Marge de seguretat més pròxim a_____mm

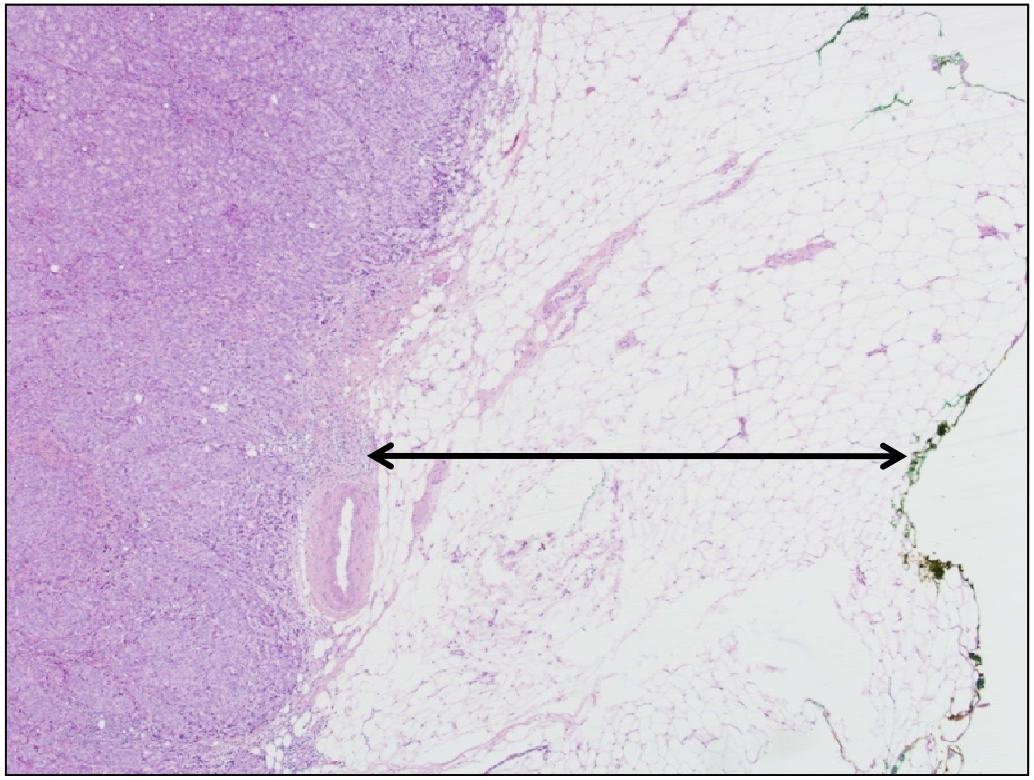

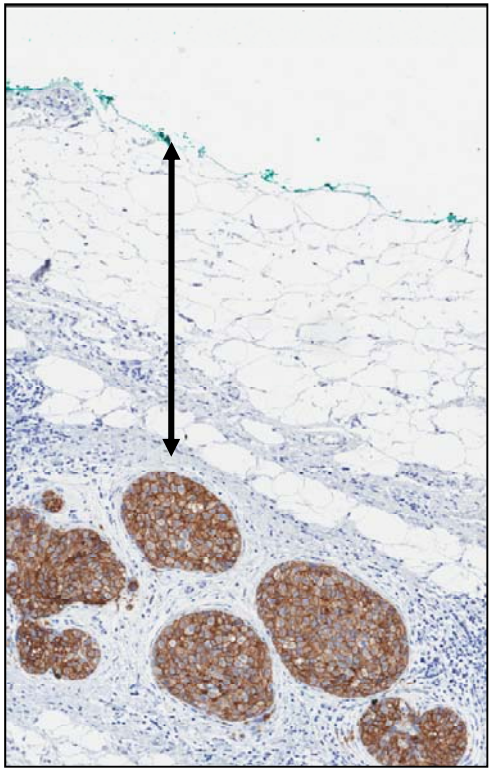

MARGES QUIRÙRGICS
(CAP – ONCOGUIA)

Informe de Anatomía Patológica/Patología

Protocolo de mama

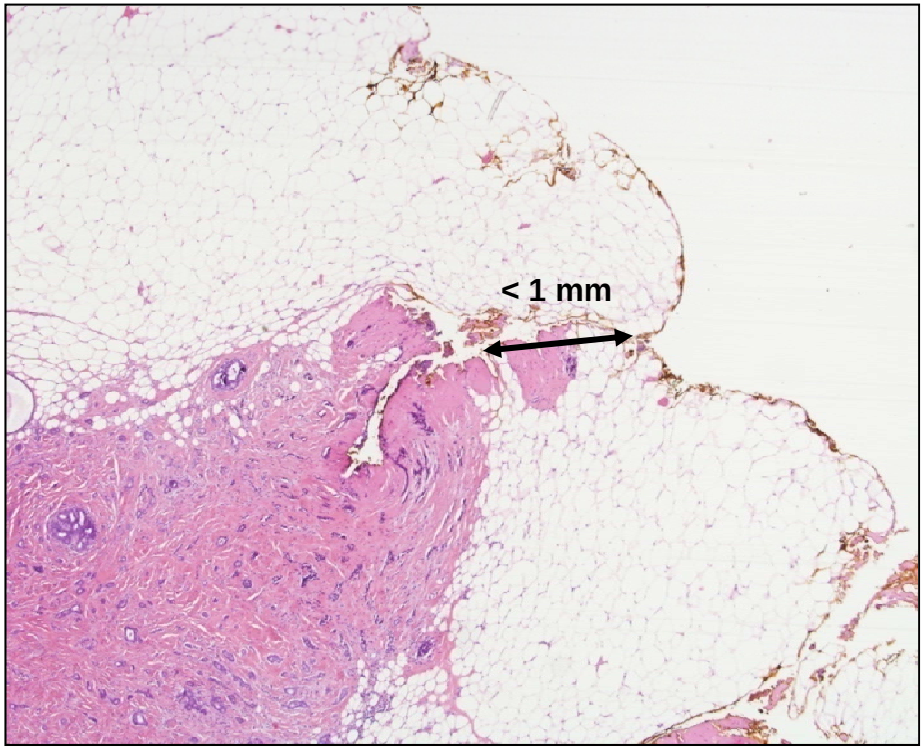

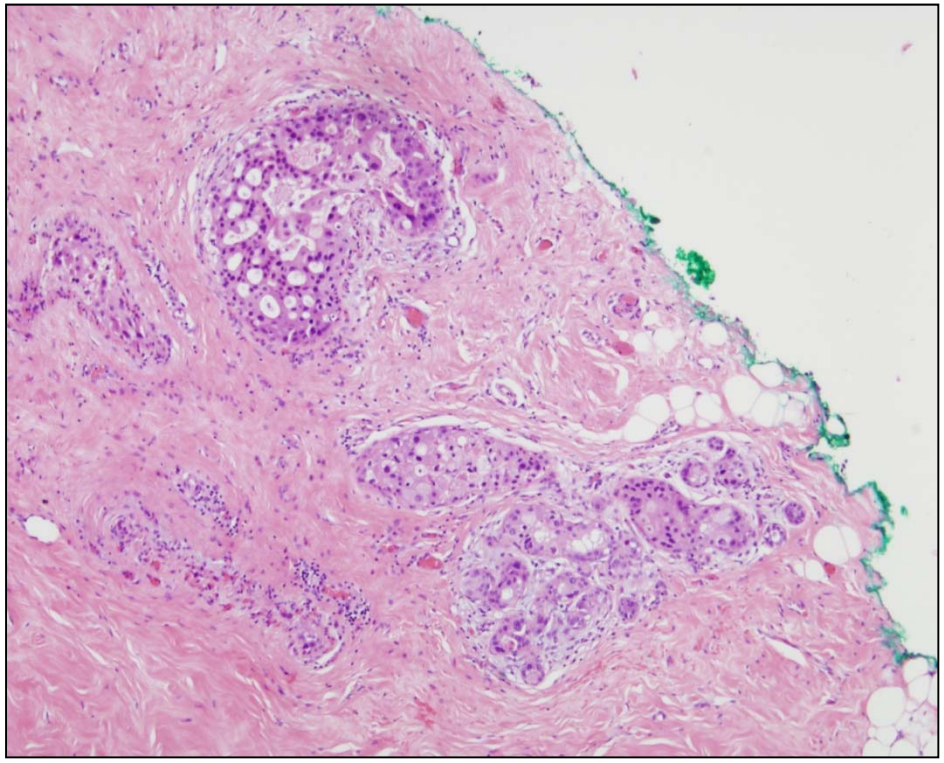

MARGES QUIRÙRGICS
(CAP – ONCOGUIA)

Informe de Anatomía Patológica/Patología

Protocolo de mama

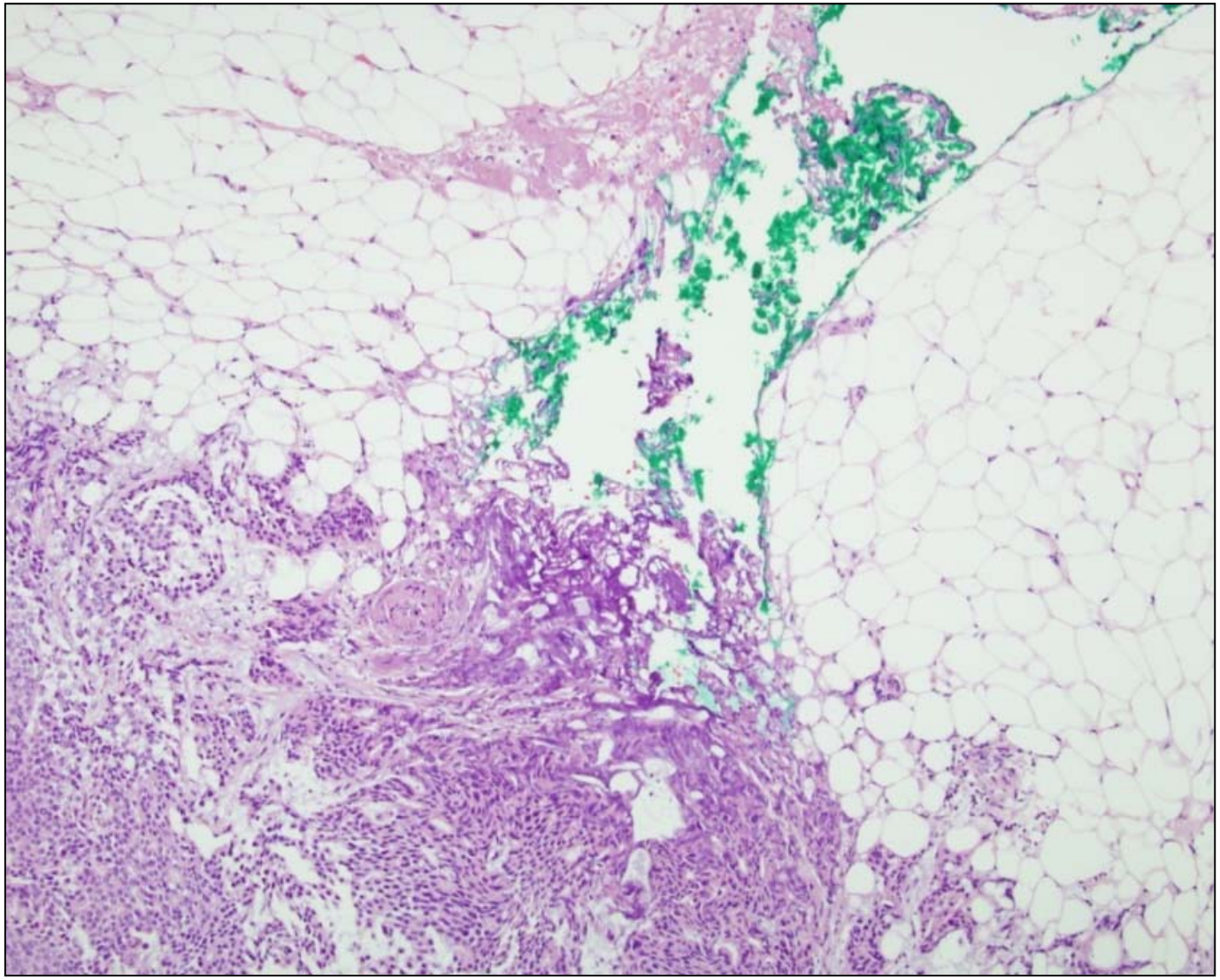

MARGES QUIRÙRGICS
(CAP – ONCOGUIA)

Informe de Anatomía Patológica/Patología

Protocolo de mama

AFECTATS (contacte amb la tinta)

Especificar:
. Marge/s
. Component infiltrant o in situ
. Extensió (mm)

(CAP: focal; mínima/moderada; extensa)

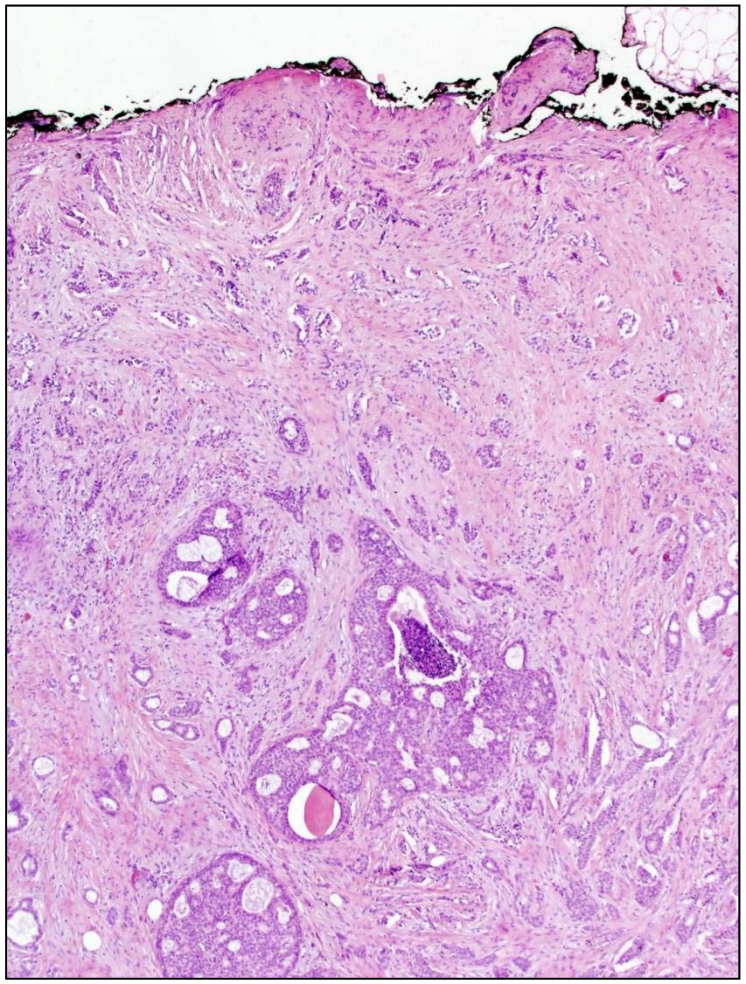

pN (UICC - 2009)



- **GANGLIS LIMFÀTICS LOCO-REGIONALS**

- **Ganglis axil·lars**
- **Ganglis mamaria interna**
- **Ganglis infraclaviculars**
- **Ganglis supraclaviculars**

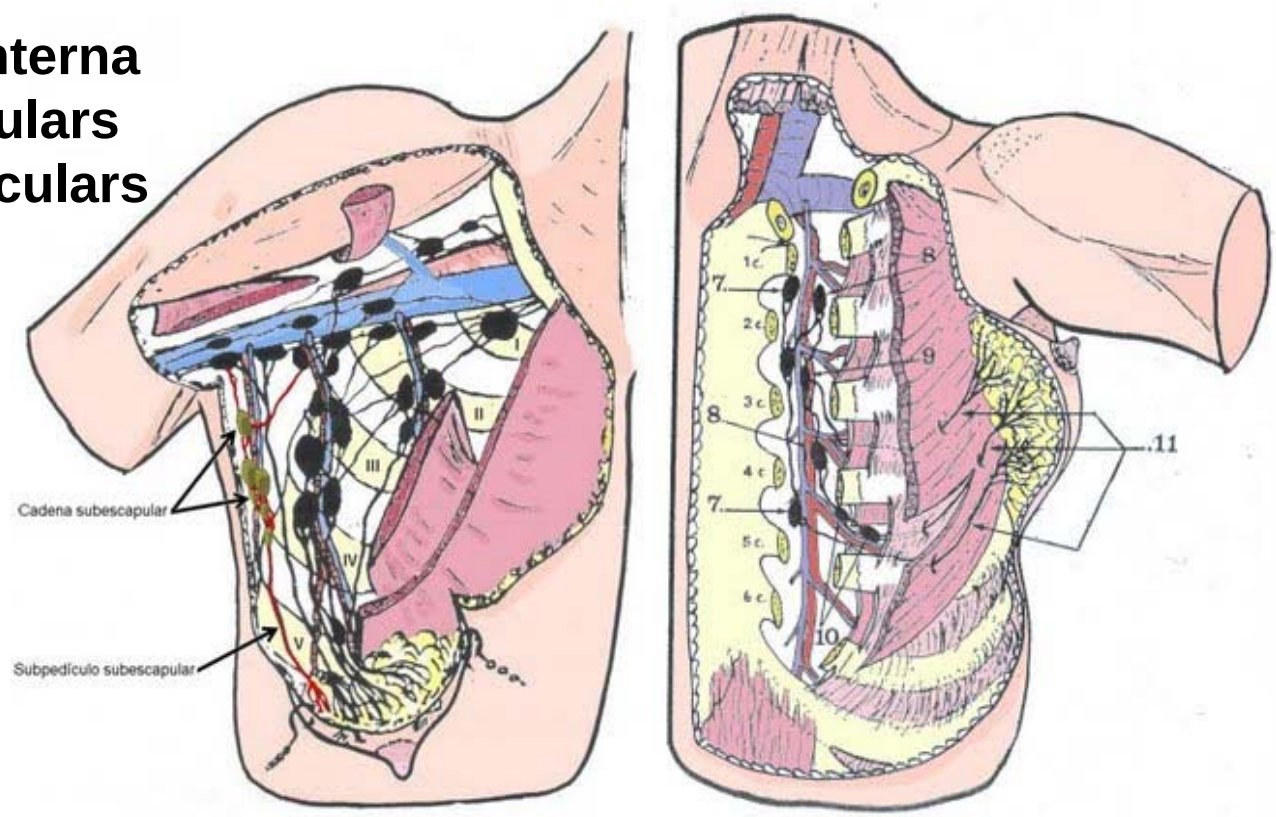

pN (UICC - 2009)



pNx (No s'han pogut estudiar els ganglis)

pN0 (ganglis sense metàstasi, no estudis adicionales)

pN0 (i-) (ganglis limfàtics negatius, també per estudi IHQ)
pN0 (i+) (ganglis limfàtics negatius histològicament, positius IHQ <0,2mm)

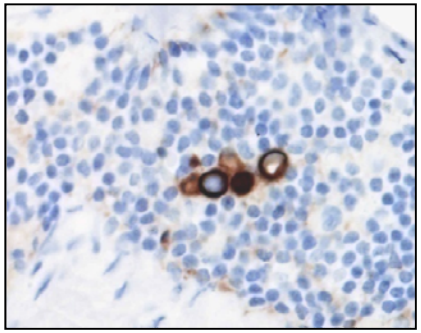

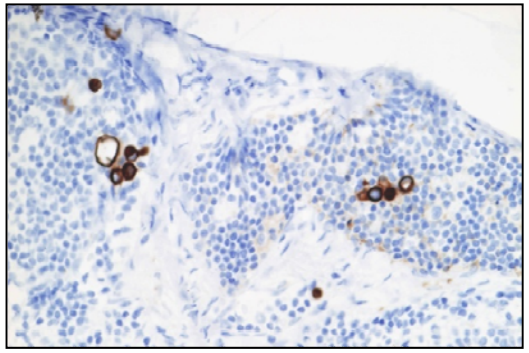

pN0 (mol -) (ganglis limfàtics negatius histològicament, negatius per RT-PCR)
pN0 (mol +) (ganglis limfàtics negatius histològicament, positius per RT-PCR)

pN (UICC - 2009)



pN1 (metàstasi d'1 a 3 ganglis limfàtics axil·lars i/o de la cadena mamària interna amb malaltia micròscopica detectada pel gangli sentinella tot i que clinicament inaparents)

pN1mi (micrometàstasis, més de 0,2 mm i/o més de 200 cèl·lules, però menys de 2 mm)

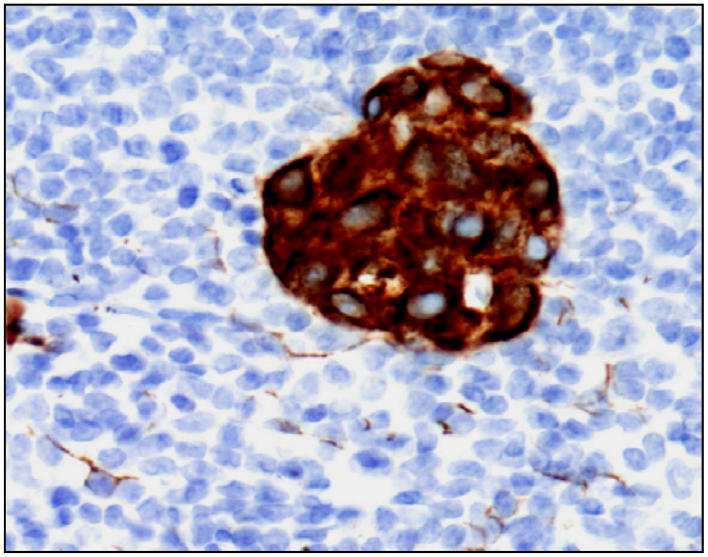

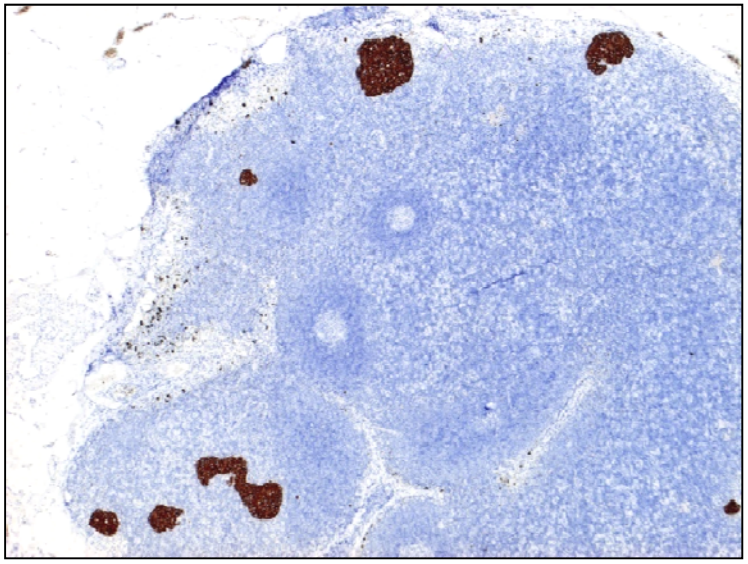

VOLUME 26 · NUMBER 11 · APRIL 10 2008

JOURNAL OF CLINICAL ONCOLOGY

ORIGINAL REPORT

Occult Axillary Node Metastases in Breast Cancer Are Prognostically Significant: Results in 368 Node-Negative Patients With 20-Year Follow-Up

Lee K. Tan, Dilip Giri, Amanda J. Hummer, Katherine S. Panageas, Edi Brogi, Larry Norton, Clifford Hudis, Patrick I. Borgen, and Hiram S. Cody III

MSKCC, 1976-1978
n 368
Cir. Mama + LA (N^-)
No Tt sistèmic adjuvant
Seguiment 17.6 anys

Disease-free survival by largest cluster size

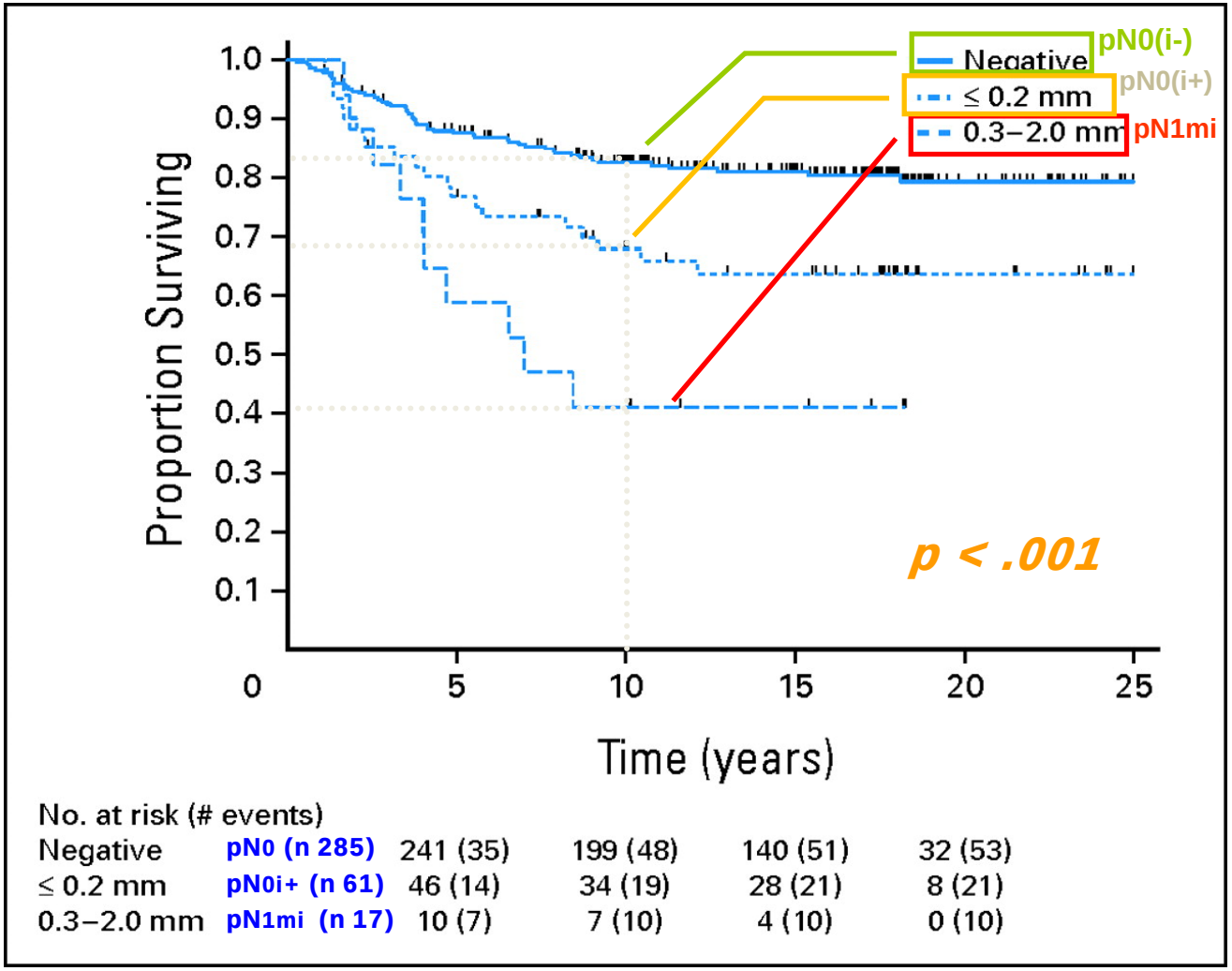

Tan, J Clin Oncol 2008

pN (UICC - 2009)



pN1a (metàstasi en 1-3 ganglis limfàtics, almenys 1 amb més de 2 mm)

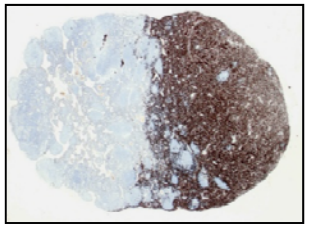

pN1b (gànglis limfàtics de la cadena mamària interna amb metàstasis microscòpica o macroscòpica detectada pel gangli sentinella encara que no clinicament aparent)

pN1c (metàstasi en 1-3 gànglis limfàtics axil·lars i ganglis de la cadena mamària interna amb metàstasis microscòpica o macroscòpica encara que no clínicament aparent)

pN (UICC - 2009)



pN2 (metàstasi en 4-9 ganglis limfàtics axil·lars ipsilaterals o de la cadena mamària interna clínicament aparents en absència de metàstasi de ganglis axil·lars)

pN2a (metàstasi en 4-9 ganglis limfàtics axil·lars ipsilaterals, al menys 1 amb més de 2 mm)

pN2b (metàstasi clínicament aparent en la cadena de la mamaria interna en absència de metàstasi a ganglis axil·lars)

pN (UICC - 2009)



pN3a

.- Metàstasi a 10 o més ganglis limfàtics axil·lars (almenys 1 amb més de 2 mm)

.- Metàstasis a ganglis limfàtics infraclaviculars

pN3b

.- Metàstasis a ganglis de la cadena mamària interna clínicament aparents amb presència a més de ganglis limfàtics axil·lars positius

.- Metàstasi a més de 3 ganglis limfàtics axil·lars positius i metàstasi a ganglis de la cadena mamaria interna detectades per estudi del gangli sentinella i clínicament negatius

pN3c .- Metàstasi a ganglis limfàtics supraclaviculars

pM (UICC - 2009)



pM0 No metàstasi a distància

pM1 Metàstasi a distància

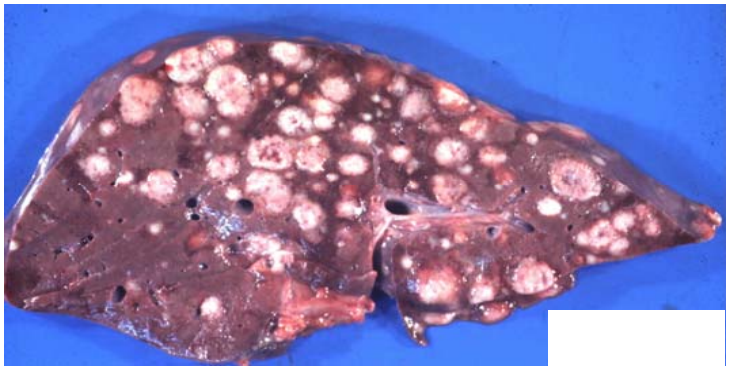

Pulmó	PUL
Ós	OSS
Hepàtica	HEP
Cervell	BRA
Moll d'os	MAR
Pleura	PLE
Adrenals	ADR
Pell	SKI

T

N

M

Mujer desnuda en un balancin - 1956
Pablo Ruiz Picasso
(1881-1973)